Scapholunate Instability: Current Concepts in Diagnosis and Management

Alison Kitay, MD, Scott W. Wolfe, MD

Injuries to the scapholunate joint are the most frequent cause of carpal instability and account for a considerable degree of wrist dysfunction, lost time from work, and interference with activities. Although it is insufficient to cause abnormal carpal posture or collapse on static radiographs, an isolated injury to the scapholunate interosseous ligament may be the harbinger of a relentless progression to abnormal joint mechanics, cartilage wear, and degenerative changes. Intervention for scapholunate instability is aimed at arresting the degenerative process by restoring ligament continuity and normalizing carpal kinematics. In this review, we discuss the anatomy, kinematics, and biomechanical properties of the scapholunate articulation and provide a foundation for understanding the spectrum of scapholunate ligament instability. We propose an algorithm for treatment based on the stage of injury and the degree of secondary ligamentous damage and arthritic change. *(J Hand Surg 2012;37A:2175–2196.* *Copyright © 2012 by the American Society for Surgery of the Hand. All rights reserved.)*

Key words Scapholunate ligament, scapholunate instability, DISI, SLAC.

Additional material is available online.

TRADITIONALLY, THE WRIST has been conceptually simplified into a dual linkage system composed of proximal and distal carpal rows, in which each bone in a given row moves in the same direction during wrist motion. However, the ligamentous connections between each bone in each row allow for subtle alterations in kinematic behavior.[1] This arrangement is potentially unstable and delicately balanced. Ligamentous or bony injuries to the wrist have the potential to irreversibly disrupt this balance, and to set the stage for an inexorable progression to abnormal motion, joint loading, and degenerative change. This review will focus on the critical importance of the scapholunate (SL) joint to carpal function. The anatomy, kinematics, and biomechanical properties of the SL articulation will be reviewed in detail to provide a foundation for understanding SL ligament instability. We will also present algorithms for managing these difficult injuries.

From the Department of Hand and Upper Extremity Surgery, Hospital for Special Surgery, New York, NY.

The authors thank Christina Kuo, MD, for her contributions to the manuscript.

Received for publication July 2, 2012; accepted in revised form July 31, 2012.

No benefits in any form have been received or will be received related directly or indirectly to the subject of this article.

Corresponding author: Scott W. Wolfe, MD, Department of Hand and Upper Extremity Surgery, Hospital for Special Surgery, 535 East 70th Street, New York, NY 10021; e-mail: wolfes@hss.edu.

0363-5023/12/37A10-0039$36.00/0
http://dx.doi.org/10.1016/j.jhsa.2012.07.035

ANATOMY

The clustering of the 8 carpals into proximal and distal carpal rows has been widely accepted, based on their kinematic behavior during global wrist motion. The 5 bones of the distal carpal row (trapezium, trapezoid, capitate, and hamate) are tightly bound to one another via stout intercarpal ligaments, and motion between them can be considered negligible. Similarly, the nearly rigid ligamentous connection of the trapezium and capitate to the index and middle metacarpals allows us to consider the distal row functionally as part of a fixed hand unit that moves in response to the musculotendinous forces of the forearm. The scaphoid, lunate, and triquetrum can be described as an intercalated segment, because no tendons insert upon them.[2,3] Their motion entirely depends on mechanical signals from their surrounding articulations, checked by an intricate system of intrinsic, or interosseous, and extrinsic carpal ligaments.

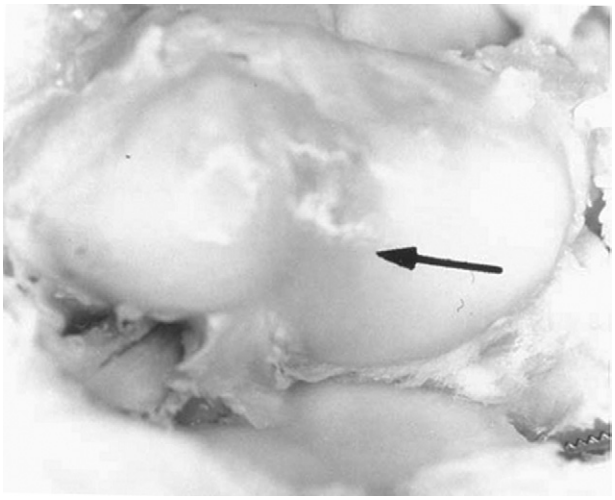

FIGURE 1: The SLIL (arrow) creates a seamless transition between the articular surfaces of the scaphoid and lunate. (Reprinted with permission from Kuo CE, Wolfe SW. Scapholunate instability: current concepts in diagnosis and management. J Hand Surg 2008;33A:998–1013. Copyright © Elsevier.)

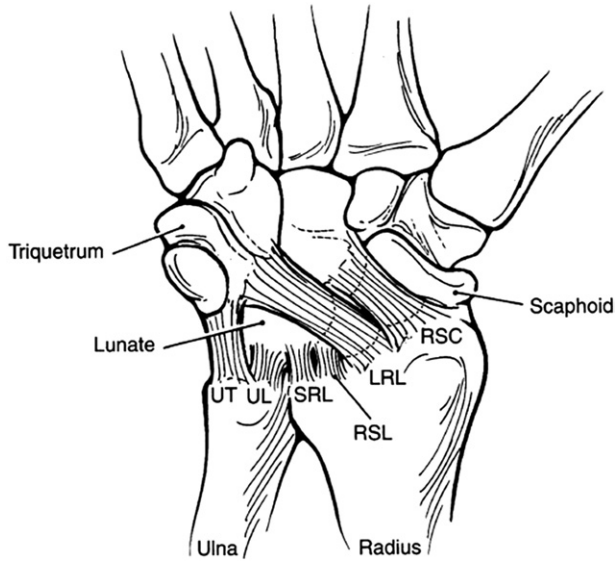

FIGURE 2: The stout extrinsic volar ligaments serve as secondary stabilizers of the SL joint. LRL, long radiolunate ligament; SRL, short radiolunate ligament; RSC, radioscaphocapitate ligament; RSL, radioscapholunate ligament; UT, ulnotriquetral ligament; UL, ulnolunate ligament. (Reprinted with permission from Ruch DS, Poehling GG. Arthroscopic management of partial scapholunate and lunotriquetral injuries of the wrist. J Hand Surg 1996;21A:412–417.)

The most frequently injured of these intercarpal relationships is the SL joint. When viewed through an arthroscope or at arthrotomy (Fig. 1), the normal scaphoid and lunate appear nearly seamless, bound together by a tough SL interosseous ligament (SLIL). The SLIL is C-shaped and attaches exclusively along the dorsal, proximal, and volar margins of the articulating surfaces, leaving a crevice between the bones distally. The 3 subregions of the ligament have different material and anatomic properties, and the dorsal component is the thickest, strongest, and most critical of the SL stabilizers.[4,5] The dorsal component is a true ligament with transversely oriented collagen fibers, and is a primary restraint not only to distraction, but also to torsional and translational moments. The palmar SL ligament, although considerably thinner, has important contributions to rotational stability of the SL joint. The proximal membranous portion of the SLIL appears histologically as a fibrocartilaginous structure, and in isolation, contributes little to no restraint to abnormal motion of the SL joint.

WRIST MECHANICS

As the anterior cruciate ligament is considered the primary stabilizer of the knee, so, too, can the SLIL be considered the primary stabilizer of the SL joint, if not the entire carpus. It is surrounded in turn by several secondary stabilizers, each insufficient to cause instability after isolated disruption, but each important in the maintenance of normal SL kinematics. The secondary stabilizers are vulnerable to attritional wear after complete disruption of the SLIL. On the volar-radial side are the stout extrinsic ligaments: the radioscaphocapitate ligament, the long and short radiolunate ligaments, and the radioscapholunate ligament (of Testut) (Fig. 2). The relative importance of each of these ligaments to SL stability has not been definitively established, but the radioscapholunate ligament, once thought to be a critical stabilizer of this joint, is now regarded primarily as a neurovascular conduit with little mechanical integrity. The volar-ulnar extrinsic ligaments include the ulnolunate and ulnotriquetral ligaments, which are predominantly involved in stabilizing the triquetrolunate and ulnocarpal joints. Distally, the scaphotrapezial ligamentous complex has been identified as an important secondary stabilizer of the scaphoid in biomechanical studies.[6–8]

The dorsal ligamentous structures are also important secondary stabilizers of the SL joint. Both the dorsal radiotriquetral and dorsal intercarpal ligaments (DIC) have attachments to the lunate. The thickest portion of the DIC inserts on the dorsal groove of the scaphoid, whereas a thinner arm of the ligament inserts onto the dorsal trapezium and proximal trapezoid. Cadaver studies have shown that the unique V-arrangement of the

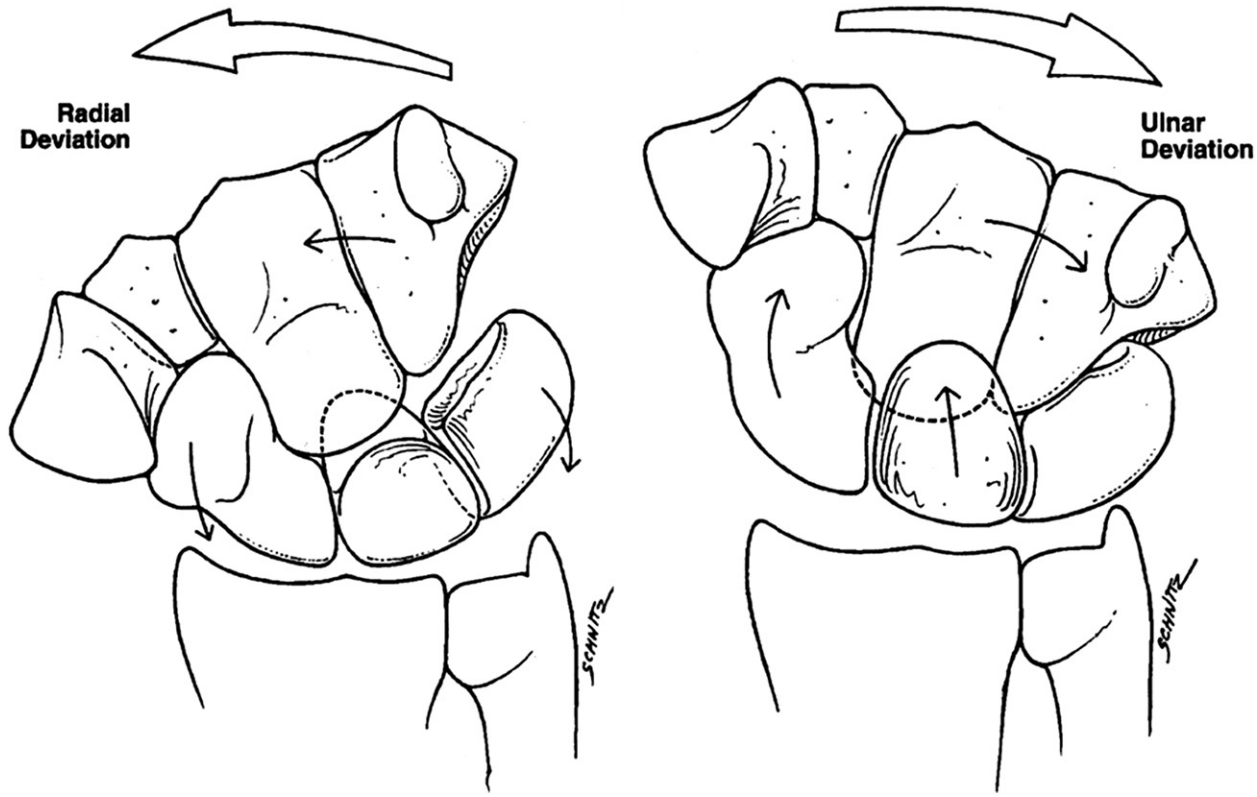

FIGURE 3: The unique helicoidal surface of the triquetrohamate joint converts ulnar deviation of the hamate into a conjoined rotation of the triquetrum into palmar displacement and dorsiflexion. (Reprinted with permission from Kuo CE, Wolfe SW. Scapholunate instability: current concepts in diagnosis and management. J Hand Surg 2008;33A:998–1013. Copyright © Elsevier.)

DIC and dorsal radiotriquetral confer important secondary stability to the SL complex during repetitive wrist motion.[9]

Thus, normal kinematics of the SL joint are tightly governed by a tough intrinsic ligament that binds the scaphoid to the lunate proximally, and an envelope of surrounding extrinsic ligaments that are oriented obliquely to the flexion-extension axis of wrist motion. The scaphoid, lunate, and triquetrum rotate collectively in flexion or extension depending on the direction of hand motion. As the hand flexes or radially deviates, mechanical forces from the distal carpal row drive the distal scaphoid into flexion, and the lunate follows passively into flexion through the strong SLIL. As the hand ulnarly deviates, the unique helicoidal articular surface of the hamate engages the concordant surface of the triquetrum and, via a screwlike engagement, directs it into a dorsally tilted and palmarly translated position (Fig. 3).[10] The lunate and scaphoid rotate into extension through a combined effect of their unyielding interosseous ligaments and the coupled rotation of the distal row into a dorsally translated position. Dorsal translation of the distal row effectively tensions the radioscaphocapitate and scaphotrapezial ligaments, and hoists the scaphoid into extension. During hand or wrist extension, the intercalated segment rotates as a unit, as tension in the extrinsic ligaments locks the scaphoid, lunate, and triquetrum to the capitate in conjoined extension.[1] Macconnail[11] explained this phenomenon and cited the critical role of the dorsal intercarpal ligament in producing a unified motion of the bones of the proximal and distal carpal rows, by a screw-clamp mechanism that captures the capitate between the scaphoid and triquetrum as the ligament tightens.

Whereas the scaphoid, lunate, and triquetrum all rotate in the same primary direction during hand positioning, there is considerable multiplanar motion that occurs between each bone at the interosseous joints. This multiplanar motion is attributable to the unique design and character of the interosseous ligaments. During a 120° arc of flexion and extension, for example, scaphoid flexion-extension exceeds lunate flexion-extension by approximately 35°. Scaphoid pronation is approximately 3 times that of lunate pronation during wrist flexion, and lunate ulnar deviation exceeds scaphoid deviation considerably.[1] Interestingly, during wrist and hand extension, both the primary and out-of-plane rotations of the scaphoid and lunate are more tightly

coupled, which may partly result from the influence of the dorsal extrinsic ligaments mentioned above.

The literature is rife with controversy concerning the relative contribution of different carpals to global wrist motion, and whether the scaphoid can be considered kinematically part of the proximal carpal row, or rather an independent coupling link between the proximal and distal rows.[12–14] Recent studies focused attention on coupled motion of the wrist—that is, combination motions of flexion-extension and radioulnar deviation, such as the dart thrower's motion (DTM) of radial-extension to ulnar-flexion.[15–19] This oblique path of motion has been postulated to be uniquely human[19] and is widely used in occupational activities such as hammering or pouring from a pitcher,[20] as well as in sports and recreational activities.[17] Kinematic studies during this functional arc of motion have demonstrated a remarkable degree of consistency between subjects and between investigators, and show that the scaphoid and lunate demonstrate minimal motion relative to each other or to the radius during the DTM.[15,16,18] The implications of these findings are broad and include the potential to develop rehabilitation programs after wrist injury or repair that incorporate the DTM and reduce strains on the SL interosseous ligament during wrist motion.

The redundancy of primary and secondary ligament stabilizers explains why division or injury to a single supporting ligament is generally insufficient to cause abnormalities in scaphoid or lunate posture on static radiographs. Even a complete division of the SL ligament may cause no static increase in SL gap or change in lateral SL angle acutely. Nevertheless, dramatic changes in force transmission and kinematics of the 2 bones during wrist motion occur after SLIL division, and likely explain the symptoms of catching, popping, and pain seen in dynamic SL instability.[5,8,21] Additional division of 1 or more of the secondary restraining ligaments is necessary before static changes in scaphoid and lunate posture are seen, and these changes have been documented after transection of the volar extrinsic ligaments, the dorsal intercarpal ligament, and the scaphotrapezial ligaments.[6–9,22,23] Attritional wear of the secondary restraints is thought to cause delayed development of dorsal intercalated segment instability (DISI) after isolated disruption of the SLIL.[24] Differences in the bony anatomy of the radioscaphoid articulation have been postulated to affect scaphoid stability after soft tissue injury, and may help explain why some patients go on to progressive instability and others do not.[25] Rhee and colleagues[26] demonstrated an association between lunate morphology and the development of DISI after SL dissociation. In that study, type II lunates were associated with a significantly lower incidence of DISI after complete SLIL tears.

FIGURE 4: Previous definitions of SL instability relied on demonstration of grossly abnormal posture of the carpals on static radiographs. Note increased SL interval after attempted operative stabilization. (Reprinted with permission from Kuo CE, Wolfe SW. Scapholunate instability: current concepts in diagnosis and management. J Hand Surg 2008;33A:998–1013. Copyright © Elsevier.)

SCAPHOLUNATE INSTABILITY: DEFINITION

Classically, the diagnosis of SL instability was predicated on abnormal scaphoid or lunate alignment as seen on static radiographs (Fig. 4).[23] However, this definition was not inclusive enough to explain the often disabling symptoms of pain with mechanical loading or sudden shifts or "clunks" that were noted among some injured patients with normal radiographs. The concept of dynamic SL instability was proposed to describe abnormal carpal positioning that required special stress radiographs to be manifested. It is now recognized that SL instability is a spectrum of injury rather than an all-or-none condition (Table 1).[7,27–29] Scapholunate instability is defined as a wrist that is symptomatic during mechanical and load-bearing activities, demonstrating abnormal kinematics during motion.[30]

TABLE 1. Geissler Arthroscopic Grading System[55]

Grade	Description
I	Attenuation/hemorrhage of SLIL (viewed from radiocarpal space). No midcarpal malalignment
II	Attenuation/hemorrhage of SLIL (viewed from radiocarpal space) AND stepoff/incongruency of carpal alignment. Slight gap between carpals (less than width of probe)
III	Stepoff/incongruency of carpal alignment (viewed from both radiocarpal and midcarpal space) AND SL gap large enough to pass probe between carpals
IV	Stepoff/incongruency of carpal alignment (viewed from both radiocarpal and midcarpal space), gross instability, AND 2.7-mm arthroscope can pass through the gap between the scaphoid and lunate (positive "drive-through sign")

CLINICAL SIGNS

The SL ligament can be disrupted through a variety of mechanisms and injuries. Often, patients report a history of a fall with impact to the hypothenar region of the hand. Mechanical studies demonstrate that this ligament fails as the wrist is forcibly extended while in a position of ulnar deviation and supination.[31] A high index of suspicion is necessary to correctly diagnose an acute SL ligament disruption in the emergency department. Tenderness is usually poorly localized about the periscaphoid area, and pain will generally preclude provocative wrist ligament testing. Diffuse swelling may obscure the characteristic wrist effusion, which is indicative of a serious intra-articular injury. Arthrocentesis is helpful when the history is suggestive and radiographs are normal; the identification of a hemarthrosis implies a serious ligament injury in the face of negative x-rays. Vascular or neural compromise is rare, except in extreme ligament injuries such as lunate or perilunate disruption.

Patients with subacute injuries (1–6 wk) often present with a history of painful popping or clicking with activities, decreased grip strength, and well-localized tenderness about the scaphoid and dorsal SL interval. Watson et al[32] described a provocative maneuver known as the scaphoid shift test that can detect subtle degrees of scaphoid instability. The examiner's thumb applies pressure to the scaphoid tubercle as the patient's wrist is brought from a position of ulnar deviation and slight extension to radial deviation and slight flexion (Fig. 5). The scaphoid will normally flex and pronate during this maneuver, but in scaphoid instability the maneuver will be painful, and thumb pressure will force the proximal scaphoid from the scaphoid fossa onto the dorsal articular lip of the radius. Relief of thumb pressure allows the scaphoid proximal pole to spontaneously reduce, often with an audible or palpable "clunk." The test may be falsely positive in up to one-third of individuals, and is thought to result from ligamentous hyperlaxity that permits capitolunate translation with similar findings.[33,34] Patients with an appropriate history and a positive scaphoid shift test should be considered as having a suspected SLIL disruption and should be evaluated further with appropriate imaging or arthroscopy.

RADIOGRAPHS

High-quality posteroanterior (PA), lateral, navicular, and anteroposterior (AP) grip radiographs should be obtained, and contralateral wrist radiographs are necessary for comparison.[3] Lateral radiographs should be carefully evaluated for adequate technique, and they should be repeated if the radius, capitate, and long finger metacarpal are not roughly collinear in the sagittal plane. Yang et al[35] recommended that the scaphoid tubercle and pisiform be maximally superimposed to assure a true lateral scaphopisocapitate radiograph of the wrist.

Measurement of intercarpal angles on static films is difficult and subject to a great degree of variability among examiners. It is nearly impossible to precisely and reproducibly determine the position of a bisecting line in each irregularly shaped small carpal. Approximation of intercarpal angles using tangents to the external contour of each bone is an easier and equally reliable technique.[36] The examiner draws a tangent to the palmar cortex of the scaphoid proximal and distal poles, and a second tangent to the distal articular surface of the lunate palmar and dorsal lips (Fig. 6). A perpendicular is drawn from the lunate tangent to determine lunate posture in the sagittal plane. Deviation of this line from the longitudinal axis of the radius (the radiolunate angle) by more than 15° in the dorsal direction on a true lateral film indicates DISI. Although it is unusual with SL ligament injuries, a radiolunate angle of more than 15° in the volar direction indicates volar intercalated segment instability. The scapholunate angle is measured between the scaphoid tangent and the

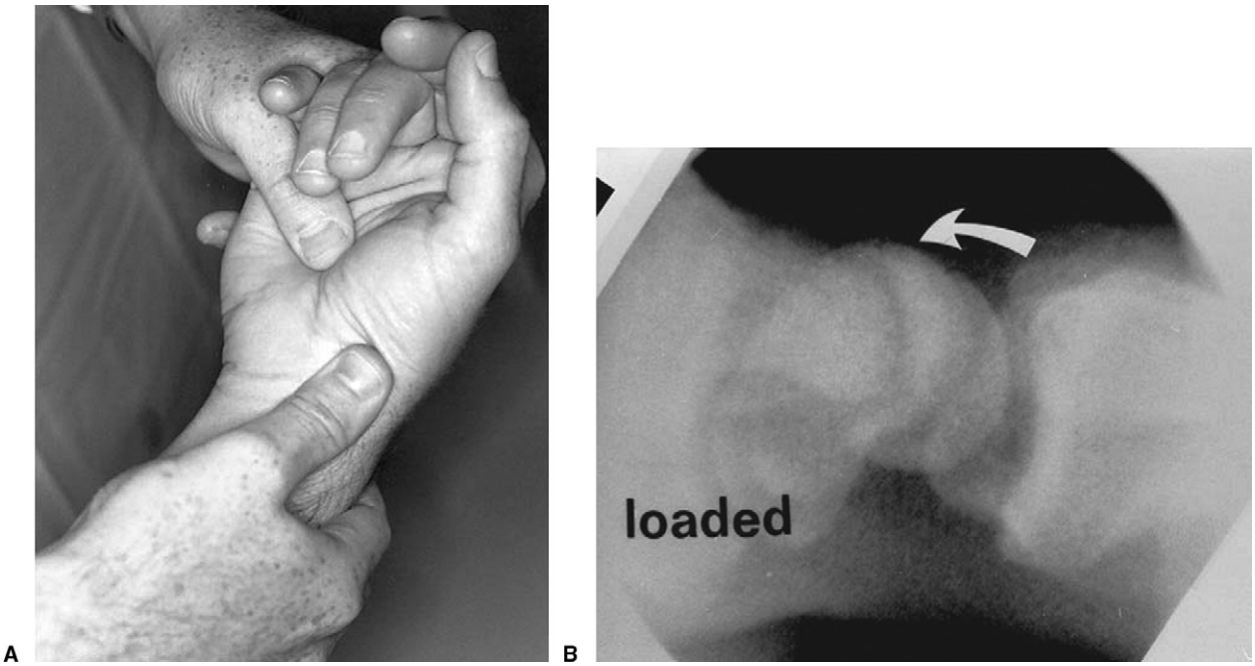

FIGURE 5: A During the performance of the scaphoid shift test, the examiner's thumb applies pressure to the scaphoid tubercle while the subject's hand is moved from ulnar deviation and slight extension to radial deviation and slight flexion. **B** Fluoroscopic view of a positive scaphoid shift test, demonstrating subluxation of the proximal scaphoid from the scaphoid fossa of the distal radius (arrow). (Reprinted with permission from Kuo CE, Wolfe SW. Scapholunate instability: current concepts in diagnosis and management. J Hand Surg 2008;33A:998–1013. Copyright © Elsevier.) A Video is available on the *Journal's* Web site at www.jhandsurg.org that demonstrates the scaphoid shift test.

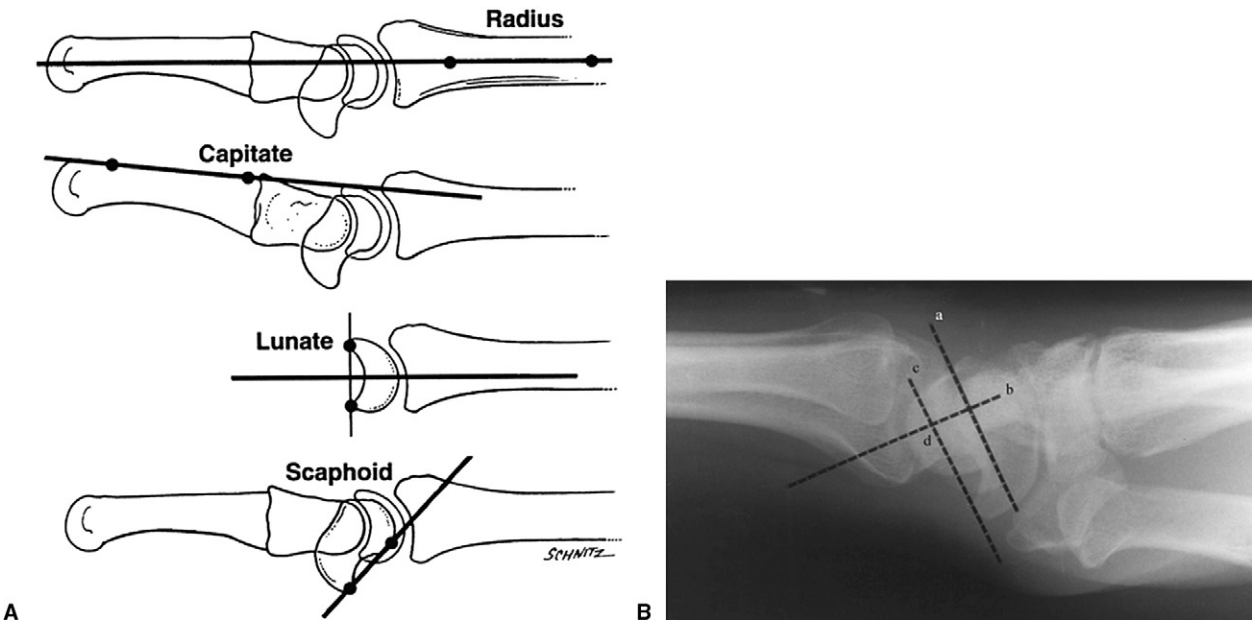

FIGURE 6: Reproducible measurement of intercarpal angles is facilitated by drawing tangents to the carpal contours. **A** Note that the lunate axis is perpendicular to the lunate tangent line. **B** Lunate tangent (*a*), lunate axis (*b*), scaphoid tangent (*c*). This lateral radiograph shows a 20° DISI posture of the lunate and a (*d*) 90° SL angle. (Reprinted with permission from Kuo EC, Wolfe SW. Scapholunate instability: current concepts in diagnosis and management. J Hand Surg 2008;33A:998–1013.)[36]

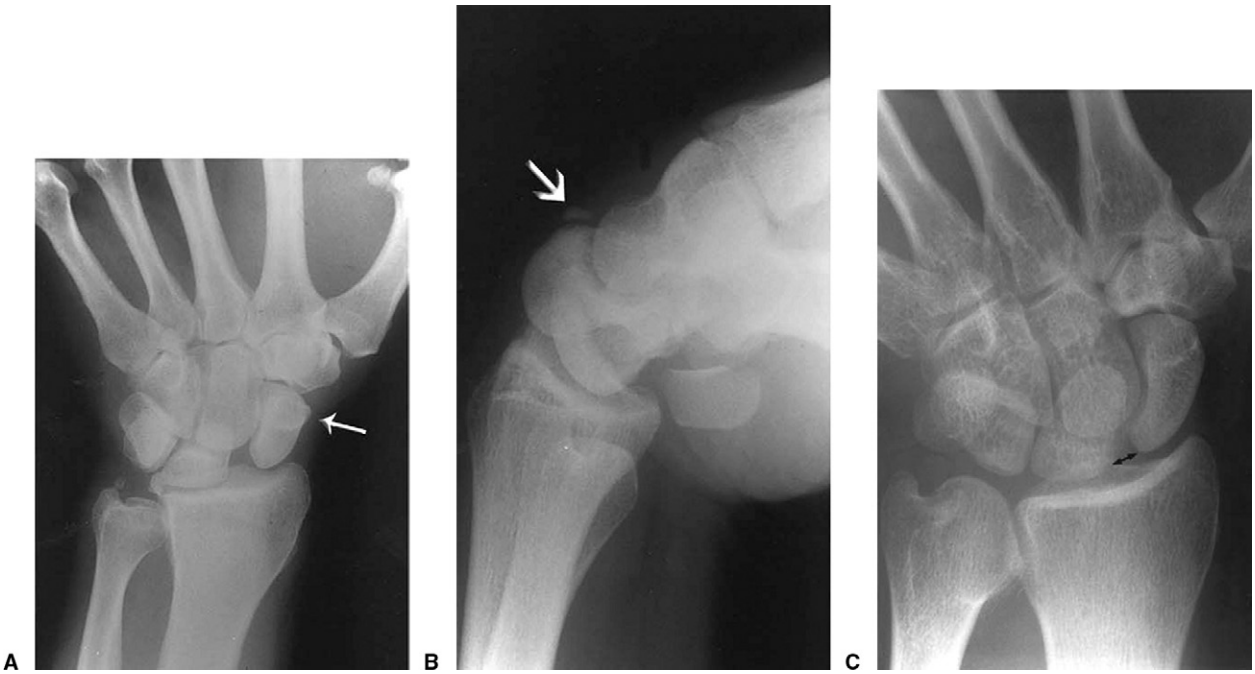

FIGURE 7: Radiographic evaluation of SL instability. **A** The scaphoid tubercle becomes superimposed on the scaphoid waist in a posteroanterior radiograph when the scaphoid is abnormally flexed, creating the so-called ring sign (arrow). **B** A full-flexion stress view shows abnormal scaphoid subluxation dorsally with minimal conjoined flexion of the lunate. A fleck of avulsed bone from the SLIL dorsal insertion site on the scaphoid can be identified (arrow). **C** Ulnar deviation view shows abnormal widening of the SL interval. (Reprinted with permission from Kuo CE, Wolfe SW. Scapholunate instability: current concepts in diagnosis and management. J Hand Surg 2008;33A:998–1013. Copyright © Elsevier.)

perpendicular to the lunate tangent, and normally measures 46° (range, 30° to 60°). A unilateral SL angle of greater than 70° is considered highly suggestive of increased flexion, or rotatory subluxation of the scaphoid.[28] Capitate posture can be approximated by a tangent to the dorsal cortex of the long finger metacarpal, and a flexed capitolunate joint in excess of 15° signifies collapse of the midcarpal joint and confirms a DISI deformity.

Other radiographic signs of advanced stages of SL instability include SL diastasis, a positive ring sign, and foreshortening of the scaphoid on the PA film. A PA static film or AP grip stress film demonstrating unilateral widening of the SL joint in excess of the width of other intercarpal joints (2–3 mm) is considered suspicious but not diagnostic of SL dissociation.[37] There is considerable normal variability in SL joint configuration, and differences in radiographic technique and wrist posture account for a high degree of variance in these measurements.[38] The scaphoid ring sign is visible on a PA film when the distal scaphoid tubercle is superimposed on the scaphoid waist (Fig. 7). When the scaphoid is flexed more than 70°, it appears foreshortened on the PA film, compared with films of the uninjured wrist.

STRESS RADIOGRAPHS

Stress radiographs are obtained when carpal instability is suspected clinically but static radiographs are normal. Several different types of stress views have been described[39]; the AP grip film is used most frequently. The AP grip film profiles the SL joint and demonstrates pathologic SL widening under axial loaded conditions. Care should be taken to position the wrist in neutral flexion-extension. Lateral full flexion and full extension radiographs can be examined for subtle differences in intercarpal motion, and are most useful when compared with similar films from the uninjured wrist. A full flexion lateral will on occasion demonstrate frank subluxation of the scaphoid proximal pole onto the dorsal rim of the radius (Fig. 7B). Full ulnar and full radial deviation PA radiographs may also demonstrate abnormal widening of the SL joint (Fig. 7C). The so-called carpal stress test, a PA film with the thumb and index fingers under traction, can also aid in diagnosis, especially when it demonstrates a stepoff at the SL joint.[40]

A recent cadaveric study[39] compared 8 different radiographic stress views and determined that the

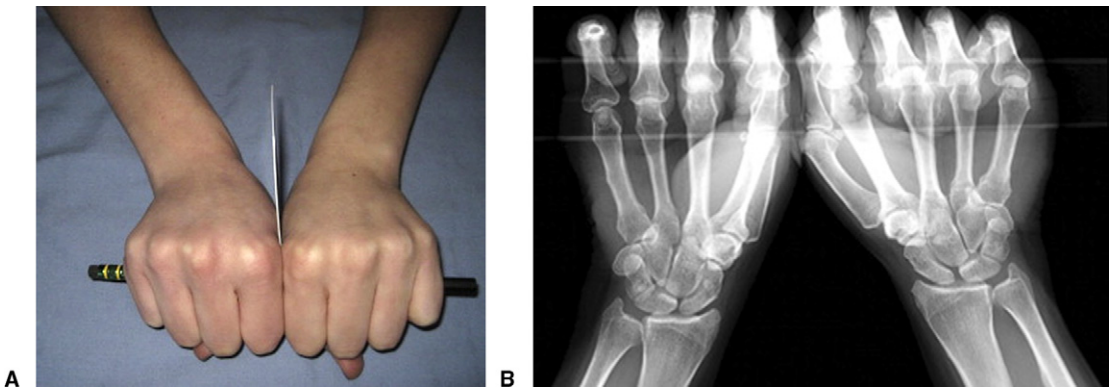

FIGURE 8: The clenched pencil dynamic stress view is performed with the forearm in pronation. **A** Clinical photograph of proper patient positioning for the clenched pencil stress view. **B** Radiographic image of the clenched pencil dynamic stress view demonstrating widening of the SL interval on the patient's right wrist. (Reprinted with permission from Lee SK, Desai H, Silver B, Dhaliwal G, Paksima N. Comparison of radiographic stress views for schapholunate dynamic instability in a cadaver model. J Hand Surg 2011;36A:1149–1157. Copyright © Elsevier.)

clenched pencil view ("pencil-grip PA") is the most useful stress view for diagnosing dynamic SL instability. The view is performed with both forearms in pronation (Fig. 8) and provides a contralateral comparison view on a single radiograph. Normal static and stress films in the acute situation do not always rule out serious injury, and patients with suspected acute SLIL injury should be immobilized and referred for immediate diagnostic evaluation.

ADVANCED IMAGING STUDIES

Advanced imaging studies may be helpful confirming a suspected diagnosis of SL ligament injury, but should not be used in isolation because of potential false-positive results.[33,41] Several authors have demonstrated a high rate of bilaterally positive wrist arthrograms in patients with unilateral symptoms and/or unilateral injury; consequently, arthrography is rarely performed at this time for confirmation of SL disruption.[42,43] Arthrography had been described as more sensitive if the radiocarpal, midcarpal, and radioulnar compartments were injected separately (3-compartment arthrography), but has been all but supplanted by magnetic resonance imaging. Computed tomography arthrography has been reported as having 95% sensitivity and 86% specificity for detecting SLIL tears compared with arthroscopy, but is also rarely performed today.[44]

High-resolution magnetic resonance imaging (MRI) is now the advanced imaging modality of choice for evaluating the status of the SL ligament at our center. Reliable and accurate MR diagnosis depends on multiple factors, such as the imaging protocol, the radiologist's experience, and whether the tear is complete or incomplete. Magnetic resonance imaging with a 1.5-T magnet, with or without gadolinium injection, has been reported to have an average of only 71% sensitivity (range, 38% to 88%), 88% specificity (range, 46% to 100%), and 84% accuracy (range, 53% to 100%) in detecting SLIL tears, and high variability in normal morphology and poor interobserver reliability have also been reported.[45–51] Magee[52] reported a sensitivity of 89% and a specificity of 100% for detecting SL ligament tears using 3-T MRI.

At our institution, we rely on high-resolution, noncontrast MRI of the wrist performed using a dedicated wrist coil with the wrist positioned at the patient's side in full pronation, but in neutral with regard to radial or ulnar deviation. We use coronal, sagittal, and axial fast spin-echo moderate echo time, cartilage sensitive sequences, an in-plane resolution of 2 mm and no interslice gaps. An additional 3-dimensional T2*-weighted gradient echo sequence is performed with a slice resolution of 1 mm with no gap. Fat suppression is provided in a single coronal image with a short tau inversion recovery. We achieve good visualization of all three components of the SL ligament and its surrounding articular cartilage using these techniques, and all images are read by musculoskeletal MR–trained radiologists (Fig. 9).

Both arthrography and MRI yield only anatomic evaluations of the wrist ligaments. A diagnosis of a partial tear yields limited information concerning their functional status. With high-resolution MRI, detailed information can be given about the dorsal, membranous, and volar components of the ligament, and this information can be used in conjunction with the clinical examination for diagnostic and treatment recommendations. Cineradiography or simple fluoroscopy can be a

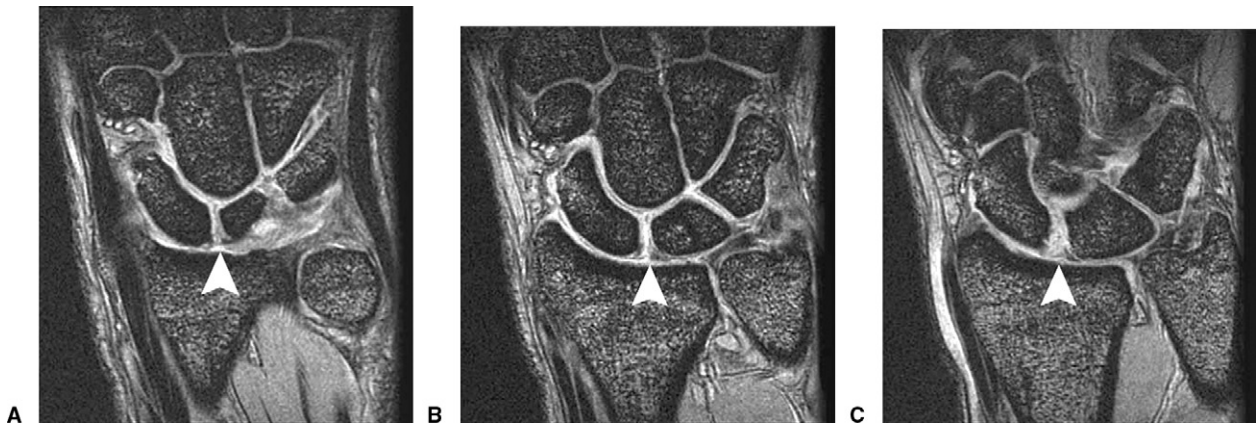

FIGURE 9: High-resolution coronal gradient echo magnetic resonance imaging of an SL tear. **A** Dorsal portion of SL tear (arrowhead). **B** Midportion of SL tear (arrowhead). **C** Volar portion of SL tear (arrowhead). (MRI images courtesy of the Hospital for Special Surgery MRI Department.) (Reprinted with permission from Kuo EC, Wolfe SW. Scapholunate instability: current concepts in diagnosis and management. J Hand Surg 2008;33A:998–1013.)

helpful ancillary study to demonstrate abnormal kinematics of the scaphoid or lunate during wrist motion, especially with ulnar to radial deviation and with wrist flexion-extension.[53]

Wrist arthroscopy yields both anatomical and functional evaluation of the interosseous and extrinsic ligaments of the wrist, and can be combined with fluoroscopic evaluation under anesthesia for valuable kinematic information.[34,54] Geissler and colleagues[55] developed an arthroscopic grading system for SLIL tears (Table 1). The ability to pass the arthroscope from the radiocarpal joint into the midcarpal joint through the SL interval (drive-through sign, Geissler grade IV) indicates complete incompetence of the SLIL and laxity or disruption of its secondary stabilizers. It cannot be overemphasized, however, that advanced imaging studies and arthroscopy should be used only to confirm a clinical diagnosis of SL injury, and treatment must be predicated on the patient's history, symptoms, and clinical examination.

CLASSIFICATION

The mildest form of SL instability, or occult instability, is usually initiated by a fall on an outstretched hand, resulting in a tear or attenuation of only a portion of the SLIL, with or without a disruption of the ligament of Testut (Table 2).[29,56] Patients with this injury may not seek treatment initially, and they may only report pain and dysfunction with mechanical loading. These patients have no abnormalities of scaphoid or lunate posture on static or stress radiographs, and fluoroscopic examination of occult injuries may be normal or abnormal. Watson et al[28] termed this condition "pre-dynamic instability," but this term implies progression toward static instability, which may not be a certainty for all patients in this category.

Higher-energy trauma may cause a subtotal or complete tear of the SL ligament, including its critical dorsal portion, with a partial extrinsic ligament injury. Untreated, these more involved injuries will predictably lead to abnormal kinematics and load transfer, with pain during activities characterized as dynamic scaphoid instability.[5,21] This is the first stage of Mayfield et al's[57] classic description of progressive perilunate instability, and may present even weeks or months after injury with relatively normal-appearing static radiographs. Abnormal stress radiographs or motion studies are necessary in this stage to confirm the diagnosis of dynamic scaphoid instability.

A complete tear of the SLIL with an additional tear or attrition of 1 or more secondary ligamentous restraints will allow the scaphoid to rotate into flexion, with a concomitant increase in the SL interval.[6,22] In this stage, known as SL dissociation, rotation of the lunate becomes independent of the scaphoid. The lunate assumes an abnormally extended posture from the extension moment transmitted through the intact triquetrolunate ligament and the dorsal translational moment imparted by the capitate. From this point on, patients will present with abnormal static radiographs. With the passage of time, a DISI deformity develops, characterized by flexion of the scaphoid, extension of the lunate and triquetrum, and dorsal and proximal translation of the capitate and distal carpal row.[3] In time, the postural changes of the scaphoid, capitate, and lunate become irreversible as the result of secondary changes in the supporting ligamentous structures. The resulting altered kinematics lead to abnormal articular

TABLE 2. Stages of Scapholunate Instability[56]

	I. Occult	II. Dynamic	III. SL Dissociation	IV. DISI	V. SLAC
Injured ligaments	Partial SLIL	Incompetent or complete SLIL; partial volar extrinsics	Complete SLIL, volar or dorsal extrinsics	Complete SLIL, volar extrinsics, secondary changes in RL, ST, DIC ligaments	As in stage IV
X-rays	Normal	Usually normal	SL gap ≥ 3 mm; RS angle ≥ 60°	SL angle ≥ 70°, SL gap ≥ 3 mm, RL ≥ 15°, CL ≥ 15°	I. Styloid DJD II. RS DJD III. CL DJD IV. Pancarpal DJD
Stress X-rays	Normal, abnormal fluoroscopy	Abnormal	Grossly abnormal	Unnecessary	Unnecessary
Treatment	Pinning or capsulodesis	SLIL repair with capsulodesis	SLIL repair with capsulodesis vs triligament reconstruction	Reducible: triligament reconstruction Fixed: intercarpal arthrodesis	Intercarpal arthrodesis or PRC

CL, capitolunate; DJD, degenerative joint disease; RL, radiolunate; RS, radioscaphoid, ST, scaphotrapezoid.

loading and, eventually, to progressive degenerative changes known as SL advanced collapse (SLAC). Arthritis first develops along the scaphoid facet of the distal radius (SLAC I), next along the proximal radioscaphoid joint (SLAC II), and finally within the radial midcarpal joint (SLAC III).[58] Although it was not described in the original report, an SLAC IV stage may ensue, involving the radiolunate joint and the entire carpus.[59] The radiolunate joint is typically spared arthritic change until many years or decades after the initial trauma because its articular surface is nearly concentric with the lunate facet of the radius in any position of rotation.

PRINCIPLES OF MANAGEMENT

Garcia-Elias et al[7] developed a set of 5 questions that provide a useful framework for developing stage-based treatment algorithms:

1. Is the dorsal SL ligament intact?
2. Does the dorsal SL ligament have sufficient tissue to be repaired?
3. Is the scaphoid posture normal?
4. Is any carpal malalignment reducible?
5. Is the cartilage on the radiocarpal and midcarpal surfaces normal?

Based on the responses to these questions, SL injuries can be grouped into 6 stages, with corresponding treatment based on each stage. Although our classification differs from that of Garcia-Elias et al in the number of categories, they are conceptually similar. The main distinction is that our scheme places all DISI deformities under a single heading, whereas the 6-stage scheme separates the reducible and fixed DISI deformities into 2 groups. Our recommendations for treatment are also based on the principles laid out by the 5 questions listed above, with the addition of 1 key concept: that the abnormal SL relationship involves 2 distinct planes of deformity.

Scapholunate dissociation describes a condition with altered kinematics in both the coronal and sagittal planes.[60] Dynamic or static widening of the SL interval indicates coronal plane instability and is best addressed by repair or reconstruction of the interosseous ligament. Rotary subluxation of the scaphoid, on the other hand, represents sagittal plane instability that results from additional injury or attenuation of the secondary ligamentous stabilizers, and is best addressed with the addition of a dorsal capsulodesis. It is important to understand that both components must be addressed to achieve successful outcomes; correcting either in isolation will predictably lead to failure.[37,61]

A STAGE-ORIENTED ALGORITHM FOR THE TREATMENT OF SL INSTABILITY

Stage 1: occult instability

Diagnosed acutely, occult instability may benefit from conservative treatment such as casting, splinting, nonsteroidal anti-inflammatories, and therapy. Arthroscopic debridement has been reported with success, and this procedure is best for patients with partial tears without clinical or intraoperative findings of instability.

Thermal shrinkage has also been recently described as an adjunct to arthroscopic debridement for the treatment of predynamic SL attenuation.[62] In this technique, a radiofrequency probe is inserted in the midcarpal joint, and thermal shrinkage is performed at the distal edge of the volar SLIL and the radioscaphocapitate ligament to help tighten the attenuated ligaments. Temporary percutaneous K-wire stabilization of the SL and scaphocapitate joints protects the heated ligaments for 2 to 4 weeks postoperatively, and therapy is typically initiated when the K-wires are removed.[62] Patients with occult instability may benefit from temporary SL pinning, whether or not thermal shrinkage is performed.

Stage 1: outcomes

Outcomes after arthroscopic debridement for occult SL instability are more favorable in patients with partial SLIL tears than complete tears. After arthroscopic debridement of partial SL ligament tears, Weiss et al[63] reported satisfactory improvement in 11 of 13 patients (85%) at a mean follow-up of 27 months. Debridement alone for complete tears fared less well, with only 10 of 15 patients (67%) reporting satisfactory improvement. Ruch and Poehling[64] reported satisfactory improvement in all 7 patients with partial SLIL tears, with no progression to instability at a minimum follow-up time of 2 years.

Early surgical results after thermal shrinkage are favorable as well. Darlis and colleagues[65] reported substantial pain relief in 14 of 16 patients treated with arthroscopic debridement and thermal shrinkage after a mean follow-up of 19 months. Of 16 patients, 8 were completely pain-free and no patients demonstrated signs of arthritis or instability during the follow-up period. Thermal shrinkage has promising short-term results, but there are potential heat-related complications to consider, including heat-generated collagen necrosis and chondrolysis given the close proximity of the articular surfaces.[31]

Stage II: dynamic instability or SL dissociation with a repairable SLIL

Patients with dynamic instability resulting from an SL ligament tear demonstrate instability in both the coronal and sagittal planes under stress examination. Each component should be addressed separately by performing a direct repair of the SLIL to correct coronal plane instability, and a dorsal capsulodesis to restore sagittal plane stability.[29,56,66,67]

Patients with SL dissociation present with static postural changes of the scaphoid and/or lunate with additional injuries to the secondary ligamentous stabilizers: the volar or dorsal extrinsic ligaments, the scaphotrapezial ligaments, or a combination injury. Patients with a reducible carpus and a strong remaining ligament are best treated by open reduction of the displaced carpals, SL repair, and a dorsal capsulodesis.

Requirements for open reduction and ligament repair include: (1) an easily reducible scaphoid, (2) a stout remaining SLIL ligament, and (3) the absence of degenerative changes. Regarding the second requirement, the SLIL degenerates fairly quickly after it is torn, which makes repairs difficult in subacute or chronic cases. High-resolution magnetic resonance imaging can be used to determine whether sufficient ligament remains for repair.

To facilitate open reduction, 1.6-mm (0.062-in) K-wires can be placed dorsally into the scaphoid and lunate and used as joysticks to rotate the scaphoid proximally and ulnarly while the lunate is rotated into neutral rotation and translated radially. It may be difficult to precisely restore the original SL relationship, but fluoroscopy can be a useful guide. In circumstances where suture anchors are planned for the SL ligament repair, the joystick K-wire can be placed at the future site of the suture anchor to prepare the bone for the anchor and avoid unnecessary drill holes in the scaphoid. When transosseous suture channels are planned for the SL ligament repair, the joystick K-wire must be placed so as not to interfere with the future transosseous tunnel sites. Once the reduction is complete, a clamp may be applied across the 2 joysticks to hold the reduced position.

In acute injuries, the SL ligament is typically avulsed from the scaphoid and remains attached to the lunate. When sufficient tissue remains, open repairs are performed with suture anchors or transosseous suture channels. Ideally, a large portion of the membranous SL ligament as well as the dorsal component of the ligament is repaired to optimize the mechanics of the repair.[68] For transosseous suture channel repairs, a burr or curette

should be used to prepare a curved channel in the articulating surface of the SL joint to receive the repaired ligament.[69] Transosseous tunnels are created across the scaphoid waist and the sutures are tied at the nonarticular waist portion of the scaphoid. Scapholunate ligament repairs are typically supported with temporary K-wires placed across the SL joint.

Dorsal capsulodesis is a critical part of the treatment for SL instability, because it addresses the sagittal plane deformity by limiting abnormal scaphoid flexion. With this procedure, the dorsal capsule is imbricated to stabilize the rotatory subluxation of the scaphoid. There are 2 techniques for dorsal capsulodesis: the traditional Blatt technique, which resists scaphoid rotation in the sagittal plane by creating a tether from the distal scaphoid to the radius,[29,66] and the modified dorsal intercarpal (DIC) ligament technique, which instead tethers the scaphoid to the lunate and triquetrum.[29,66,70–72]

In the Blatt technique, a strip of the dorsal wrist capsule is left attached to the distal radius and inserted into the scaphoid distal to its axis of rotation to prevent abnormal scaphoid flexion (Fig. 10). The proximal tether to the radius predictably leads to limitations in wrist flexion of about 20°.[37,61,66,73] In the modified DIC capsulodesis, a proximal slip of the DIC is detached from the dorsal aspect of the triquetrum and dissected back to its attachment on the distal scaphoid. After the scaphoid is reduced, the slip of the DIC is then rotated proximally and attached to the dorsal aspect of the lunate with suture anchors (Fig. 11).[31,61,67]

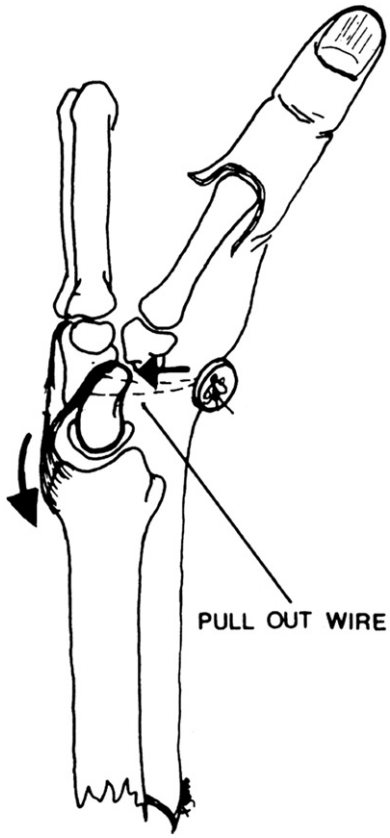

FIGURE 10: The Blatt capsulodesis procedure creates a passive dorsal restraint to abnormal flexion of the scaphoid by tethering the scaphoid to the distal radius.[56,66] (Reprinted with permission from Blatt G. Capsulodesis in reconstructive hand surgery. Dorsal capsulodesis for the unstable scaphoid and volar capsulodesis following excision of the distal ulna. Hand Clin 1987;3:81–102.)

Stage II: outcomes

Outcomes after SL ligament repairs are improved when the repairs are performed acutely and in conjunction with a capsulodesis. Both suture anchor repairs and transosseous repairs are currently used for complete SL ligament tears, and vary by surgeon preference. Bickert and colleagues[74] reported excellent or good results in 8 of 12 patients after acute SLIL repairs using Mitek Mini G2 bone anchors after a mean follow-up of 19 months. More recently, Rosati et al[75] reported excellent or good Mayo scores in 16 of 18 patients treated for acute SLIL tears with mini Mitek anchors after a mean follow-up of 32 months. Although delayed repair is considered controversial, Lavernia et al[68] demonstrated satisfactory results in a series of 21 patients with complete SLIL tears up to 3 years postinjury using the combination of transosseous ligament repair and dorsal capsulodesis.

Regarding dorsal capsulodesis outcomes, there is no current evidence to support the use of 1 method over another to augment a direct repair of the SL ligament. Moran and colleagues[61] reported no difference in outcomes between the Blatt and the modified DIC capsulodesis for chronic SL instability after a minimum follow-up of 2 years. Patients treated with both procedures had improvements in pain levels, but carpal alignment was not well maintained. Gajendran and colleagues[72] also reported long-term results after DIC capsulodesis that were comparable to long-term results after the Blatt technique. After an average follow-up of 7 years, patients demonstrated decreased wrist flexion compared with 2-year follow-up measurements, and these decreases in flexion were on the

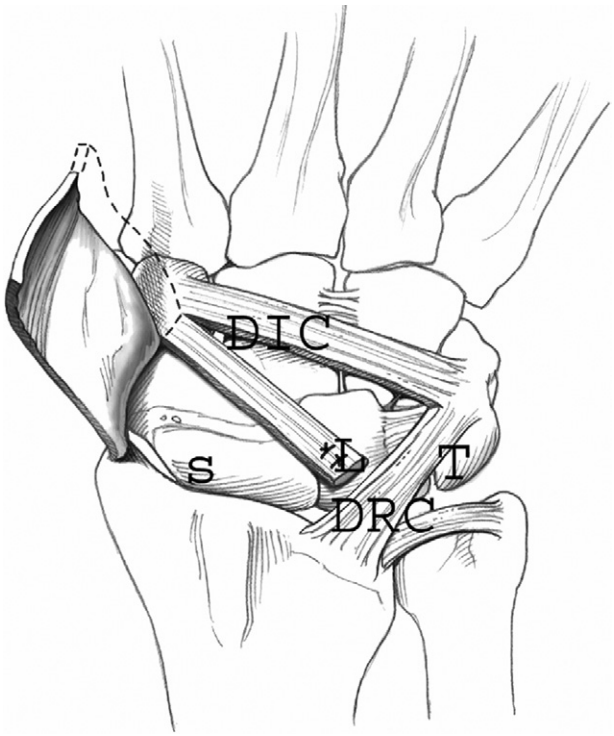

FIGURE 11: The modified DIC capsulodesis tethers the scaphoid (S) to the lunate (L), and triquetrum (T). DRC, distal carpal row. (Reprinted with permission from Manuel J, Moran SL. The diagnosis and treatment of schapholunate instability. Hand Clin 2010;26:129–144.)

same magnitude as the decreases associated with the Blatt technique.

Because SL instability represents a biplanar deformity, long-term results after combined ligament repairs with capsulodesis procedures should be superior to results after using either technique in isolation.[68] Not surprisingly, level of patient demand also has an impact on outcomes.[76] At an average follow-up of 5 years after ligament repair and capsulodesis, Pomerance[76] demonstrated that patients with strenuous jobs had significant increases in pain and SL gap under stress, and poorer subjective outcome scores than those with nonstrenuous jobs ($P < .05$).

The senior author's preferred option for a patient who presents with instability and a stout, repairable ligament is a transosseous SL ligament repair with a combined Blatt-type dorsal capsulodesis. The vector of the Blatt procedure is best aligned to counteract scaphoid malrotation in the sagittal plane. We augment the repair with 2 divergent 1.4-mm (0.045-in) K-wires across the SL joint to neutralize coronal plane forces, and a third 1.6-mm (0.062-in) K-wire across the scaphocapitate joint to control sagittal plane rotation. Although it is not a perfect solution, symptoms remain tolerable and activity levels are high.[68]

In more challenging subacute and chronic cases of SL diastasis, the senior author has moved to temporarily augmenting the SLIL repair and capsulodesis with an SL screw, especially in select populations such as high-demand athletes (Fig. 12). This is not a new concept, although previous authors have recommended that the screw be left in place permanently.[77] Concerns about K-wire loosening or breakage underlie our preference for temporary screw fixation. The screw provides more rigid fixation than K-wires when the soft tissue repairs are healing, as well as the possibility of earlier motion. We begin dart thrower's motion of the midcarpal joint at 2 months postsurgery, after removal of the scaphocapitate wire, and we remove the SL screw at 4 months postoperatively.

Stage III: reducible SL dissociation without a repairable SLIL

For patients without a repairable ligament, there are a few surgical options remaining to reestablish the critical SL linkage. Patients must have a reducible dissociation with few degenerative changes to be candidates for these reconstructive procedures. Ligament reconstruction with tendon graft, bone–ligament–bone techniques, creation of a pseudoarthrosis using a Herbert screw, and various intercarpal fusions have all been attempted with variable results.

Several tendon graft procedures have been described for SL dissociation without a repairable SLIL. Any tendon graft used to bridge the 2 dissociated carpals must have sufficient tensile strength to oppose the tremendous axial forces that drive the scaphoid and lunate apart, as well as the elasticity to permit a high degree of multiplanar rotation between the 2 bones.[1] The inability of a tendon graft to simulate the mechanical profile of a ligament has limited the effectiveness of these procedures to date.[23]

Brunelli and Brunelli[78] proposed a reconstructive procedure that used a flexor carpi radialis (FCR) tendon graft to simultaneously address the sagittal and coronal components of SL ligament instability. In that technique, a portion of the FCR is passed through the scaphoid tuberosity and sutured to the remnants of the SLIL on the dorsal aspect of the scaphoid. Next, the remaining portion of the FCR slip is anchored to the dorsal ulnar corner of the distal radius. This technique was subsequently modified to eliminate the tether to the radius and to reconstruct not only the scaphotrapezial and SL ligaments, but also the dorsal radiotriquetral ligament. This triligament tenodesis

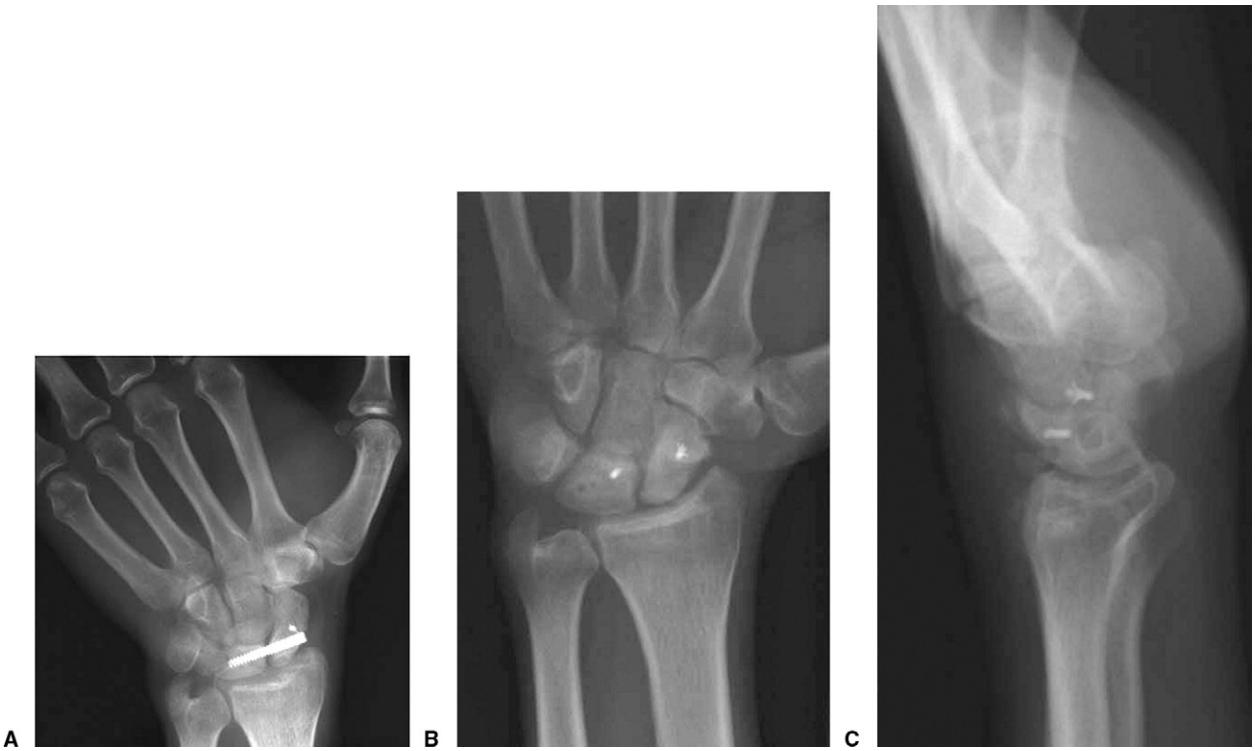

FIGURE 12: Radiographs of a 32-year-old male athlete treated with SL repair, dorsal capsulodesis, and temporary screw fixation. **A** Anteroposterior radiograph 3 months after surgery demonstrating reduction of SL interval with temporary screw fixation. **B**, **C** Anteroposterior and lateral radiograph 6 months after surgery demonstrating interval removal of SL screw and maintenance of SL reduction. (Reprinted with permission from Kuo CE, Wolfe SW. Scapholunate instability: current concepts in diagnosis and management. J Hand Surg 2008;33A:998–1013. Copyright © Elsevier.)

thereby addresses both the intrinsic and extrinsic ligament pathology (Fig. 13).[7,79–81]

Theoretical concerns arise over using a portion of the FCR as a graft, because recent work has demonstrated the importance of FCR muscle reeducation in treating dynamic SL instability. Salva-Coll and colleagues[82] performed a cadaveric study to assess the role of the FCR as a dynamic scaphoid stabilizer, and determined that FCR contraction provides stability by inducing scaphoid supination and triquetrum pronation. An alternative technique that uses the extensor carpi radialis longus tendon as a graft has recently been described for SL dissociation.[83,84] In that procedure, the extensor carpi radialis longus tendon is transferred to the distal pole of the scaphoid to prevent rotatory subluxation. Long-term clinical results are not yet available for this technique.

An alternative to soft tissue reconstruction with a tendon graft is the bone–ligament–bone reconstruction.[85–88] Several bone–ligament–bone complexes have been designed and biomechanically tested, and were previously recommended for treating SL dissociation, including the dorsal extensor retinaculum and the navicular-first cuneiform ligament of the foot.[86–88] However, graft pullout, donor site issues, and ligament stretching have been problematic,[88] and few bone–ligament–bone reconstructions continue to be used. The procedure may have a role in partial tears of the ligament rather than complete disruption with scaphoid malrotation, because isolated reconstruction of the dorsal SL ligament cannot effectively address complex multiplanar carpal malrotation.

Rosenwasser et al[89] described an alternative method for addressing stage III pathology by creating an SL pseudoarthrosis supplemented by a permanent headless screw, called the reduction and association of the scaphoid and lunate (RASL) procedure. More recently, others have described an arthroscopically assisted RASL, in which preparation of the bony surfaces and reduction of the SL articulation are performed under direct arthroscopic visualization before placing a Herbert screw (Zimmer, Warsaw, IN).

Finally, SL arthrodesis has been attempted in the past, but this procedure has been largely abandoned because of low fusion rates; successful union was identified in only 1 of 7 patients in 1 series.[90] New attempts at SL arthrodesis using vascularized bone graft have

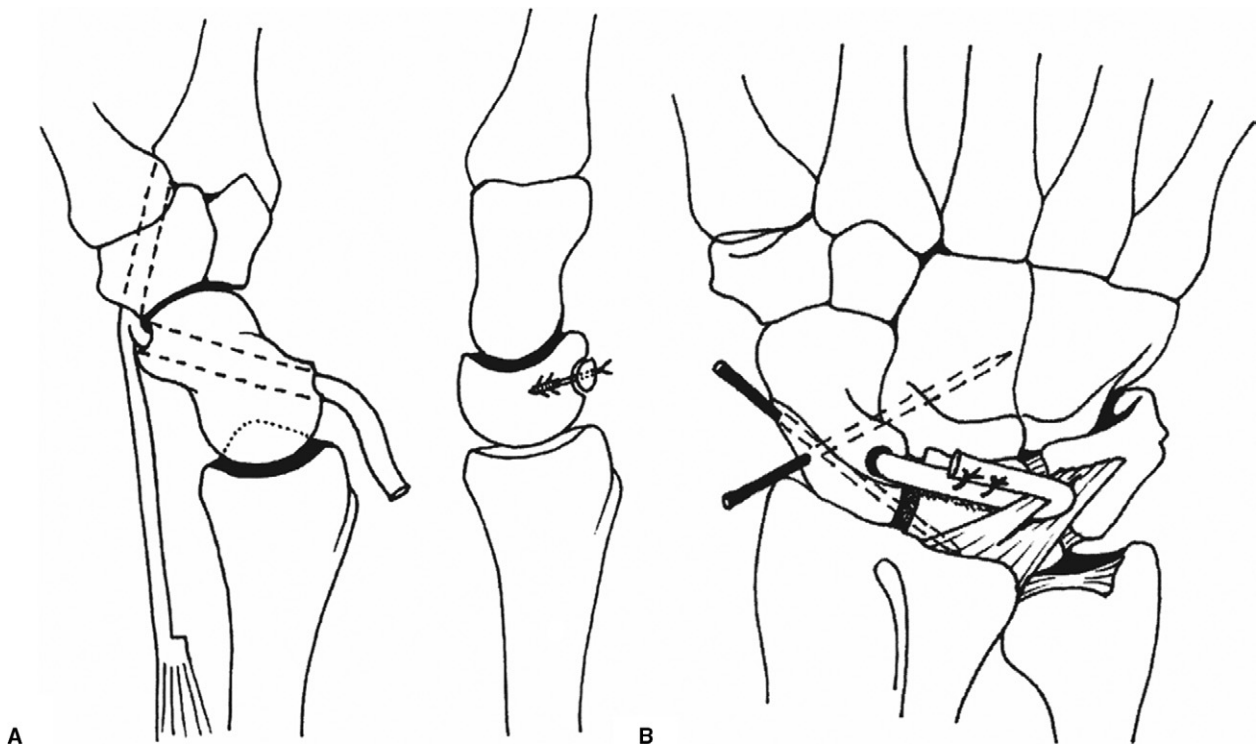

FIGURE 13: Triligament tenodesis tendon graft reconstruction. **A** A strip of FCR tendon is passed from the volar scaphoid tuberosity to the dorsal ridge to reconstruct the scaphotrapezial ligament. **B** The tendon is fixed dorsally to the lunate, passed through a slit in the dorsal radiotriquetral ligament, and sutured back on itself to recreate the SL ligament. (Reprinted with permission from Garcia-Elias M, Lluch AL, Stanley JK. Three-ligament tenodesis for the treatment of scapholunate dissociation: indications and surgical technique. J Hand Surg 2006;31A:125–134. Copyright © Elsevier.)

been proposed, but there is no supporting literature at this time.

Stage III: outcomes

Improved pain scores at midterm follow-up are achievable with most types of SLIL reconstructions, but preservation of motion and long-term maintenance of alignment continue to be problematic. A 4- to 5-year follow-up of the modified Brunelli triligament tenodesis revealed a satisfaction rate of 79%, maintenance of 65% to 80% of contralateral grip strength, and on average a 30% loss of flexion extension arc.[7,91] At this time, there is little supporting literature available for other interosseous tendon graft procedures.

There are no long-term data available for the open reduction and RASL procedure. Caloia and colleagues[92] recently reported promising early results in a series of 8 patients treated with arthroscopic RASL for SL instability with a reducible SL dissociation. The visual analog pain score in their series improved from an average of 5.4 preoperatively to 1.5 postoperatively after a mean follow-up of 34.6 months. Postoperative grip strength was 78% of the unaffected wrist, and the average postoperative wrist ROM was 20% less than the preoperative ROM. Three screws were removed because of loosening or symptomatic hardware. Conceptually, a permanent rigid construct linking the scaphoid and lunate cannot reliably reproduce the complexities of normal SL kinematics, because there is not a fixed axis of rotation for all planes of SL motion.

The senior author prefers to use triligament tenodesis in this group of prearthritic patients, because it effectively controls abnormal rotation in both planes, increases scaphoid stability to minimize painful clunks, and provides medium-term effective outcomes. To date, there is no technique that consistently provides long-term carpal stability to this challenging patient cohort.

Stage IV: dorsal intercalated segment instability, prearthritic

Massive ligament disruption at the time of injury, as may occur in perilunate or lunate dislocations, or gradual attrition of the secondary stabilizers leads to abnormal extension of the lunate and carpal collapse after SL dissociation. The lunate is forced into extension by the combined effects of the extension moment transmitted through the intact triquetrolunate ligament and the dorsal translational moment imparted by the capitate.

Without its tether to the scaphoid, the lunate drifts ulnarward, and the distal carpal row migrates proximally and dorsally. Capsular contracture may serve to fix the deformity and dictate the limited treatment options.

Nonoperative treatment is likely to result in a slow, relentless progression to degenerative arthritis, beginning first at the radial styloid, progressing proximally to involve the entire scaphoid facet, and finally reaching the midcarpal joint.[58] Depending on the chronicity of the injury and the relative activity level of the patient, the option of activity modification and splint wear may be reasonable and may forestall a motion-limiting salvage procedure. Given the relatively limited options available, many patients with well-preserved grip strength choose nonoperative treatment for years or decades, because the progression to arthritis does not follow a predictable time course.

The goals of surgery for this stage are to reduce pain, restore function, and delay the onset of degenerative changes by restoring carpal alignment and improving load distribution. If the scaphoid and lunate are reducible and no degenerative changes have occurred at the radiocarpal joint, triligament tenodesis, as described in the previous section, may be attempted. Alternatively, these patients may benefit from stabilization of the malrotated scaphoid using 1 of several intercarpal arthrodesis procedures.

For the chronic, irreducible DISI deformity without arthritis, intercarpal arthrodesis was widely recommended for years. Scaphotrapezial trapezoid arthrodesis[93] initially gained popularity in the 1980s after encouraging reports by Watson and colleagues.[94] Several authors reported satisfactory results for both dynamic and static instabilities, but concerns linger over abnormal load transmission to the distal radius and a high rate of complications in some series.[94–97] Scaphocapitate arthrodesis has also been advocated to stabilize the scaphoid, but by spanning the midcarpal joint, this procedure leads to an obligate 50% reduction in wrist motion.[98] Arthrodesis of the scaphoid, capitate, and lunate is an option that resulted in a high rate of fusion in a few small series and a relatively low complication rate.[53] Kinetic studies demonstrated a more normal distribution of load to the scaphoid and lunate facets of the radius after scaphocapitate-lunate fusion than with other partial arthrodesis procedures, although motion is predictably reduced by 50%, particularly along the dart thrower's plane.[95] The procedure has largely fallen out of favor and no recent reports have been published.

To prevent degenerative changes between the less mobile scaphoid and the remaining radial styloid after any of the intercarpal arthrodeses, most authors advocate avoiding overreducing the scaphoid and including a limited radial styloidectomy. The indications for these procedures are limited, because radiocarpal degenerative change frequently accompanies symptomatic DISI deformity. Few clinical studies are available to support widespread use of scaphoid-retaining intercarpal arthrodesis procedures. There are few predictable solutions for this challenging group of patients. Arthroscopic debridement, anterior and posterior interosseous nerve neurectomy,[99] and radial styloidectomy[100,101] can all be used as palliative treatment options to help delay more involved salvage-type procedures.

Stage V: scapholunate advanced collapse wrist

Surgical options for SLAC wrist vary by stage according to the joints that are involved. In the earliest stage of the SLAC wrist deformity, the scaphoid remains rotated into palmar flexion and its contact area with the radius is reduced and shifted dorsally. Degenerative changes are initially limited to the area of abnormal contact between the rotated scaphoid and the radial styloid. Persistent abnormal load transfer and shear across the cartilaginous surfaces leads to degeneration of the proximal scaphoid facet in stage II. With time, the dorsally translated distal carpal row migrates proximally into the widened SL interval and degenerative changes at the scaphocapitolunate joint herald stage III. The relative congruency of the radiolunate joint in all positions of lunate rotation preserves this articulation until late in the disease process, but pancarpal arthritis may ultimately ensue with disease progression. If the extent of degenerative disease is not clearly delineated on routine radiographs, computed tomography is an excellent means to individually assess changes at the midcarpal and radiocarpal articulations. Magnetic resonance imaging with cartilage-sensitive sequencing is also helpful for staging SLAC wrist patients and determining optimal treatment plans.

For patients with intractable pain who have failed a course of nonoperative treatment and corticosteroid injections, surgical treatment may be indicated. If the midcarpal joint is relatively well preserved, several midcarpal-sparing options exist. Sparing the midcarpal joint preserves coupled wrist motion along the dart thrower's plane.[19] The importance of the dart thrower's motion for performing activities of daily living has been increasingly recognized, because many tasks such as hammering require the wrist to move from a position of combined extension and radial deviation to a position of combined flexion and ulnar deviation.[102,103] Options for midcarpal-sparing surgery include radial styloidec-

tomy and radioscapholunate arthrodesis with distal scaphoid excision.[104–106] Ablative surgery includes scaphoid excision and 4-corner arthrodesis, as well as proximal row carpectomy.

Radial styloidectomy is an appropriate treatment option for patients with early-stage SLAC wrist, and it can be performed using open or arthroscopic techniques. Radial styloidectomy will not alter the progression of the degenerative process, but it may be an acceptable short- to midterm treatment for active SLAC I patients who wish to avoid intercarpal arthrodesis.

For patients with SLAC II disease with preservation of the midcarpal joint, radioscapholunate arthrodesis is a surgical option to improve pain while preserving motion through the dart thrower's plane. This procedure is typically combined with distal scaphoid excision to enhance wrist flexion-extension motion, and anterior and posterior interosseous nerve neurectomies to enhance pain relief.[105] McCombe and colleagues[107] demonstrated in a cadaver model that distal scaphoid excision increases total passive midcarpal motion after radioscapholunate arthrodesis from 60° to 122°. Simultaneous excision of the triquetrum further increases flexion and extension motion to 87% to 97% of normal, and radial and ulnar deviation to 119% to 137% of normal.[108]

Proximal row carpectomy (PRC) is an option for patients with a relatively well-preserved midcarpal joint (Fig. 14). Excision of the scaphoid, lunate, and triquetrum results in a simple hinge joint between the radius and the distal carpal row.[109] Proponents of PRC note its relative technical ease, partial preservation of wrist motion, and satisfactory restoration of grip strength.[109] It is often combined with a limited radial styloidectomy. Care must be taken to preserve the volar carpal ligaments during this procedure, to avoid ulnar drift of the carpus. Proximal row carpectomy is a time-tested treatment for lower-demand patients with stage I or II disease, but osteoarthritis progression is a known complication because of the noncongruent articular surfaces of the capitate and distal radius.[101,110]

Extensive degenerative changes at the midcarpal joint, with preservation of the radiolunate joint, are best treated with capitate–lunate–hamate–triquetral (4-corner) arthrodesis (Fig. 15). Four-corner arthrodesis can be performed for SLAC I, II, and III disease. The lunate should be reducible in the sagittal plane, and the capitate should be reduced in the coronal plane before fixation. Care should be taken to preserve the volar ligaments and the stability of the triquetrolunate joint. The dorsal lip of the distal radius can be excised if impingement is noted after fixation (Fig. 15).

FIGURE 14: A successful PRC is predicated on preservation of the volar extrinsic ligaments (represented in black) to prevent ulnar translation of the remaining distal carpal row. (Reprinted with permission from Kuo CE, Wolfe SW. Scapholunate instability: current concepts in diagnosis and management. J Hand Surg 2008;33A:998–1013. Copyright © Elsevier.)

To improve the union rate after 4-corner fusion, we recommend the use of fresh distal radius autograph and exposure to the level of bleeding, cancellous bone. Circular plate fixation should be avoided with this technique because of high complication rates.[111–113] Some authors advocate lunocapitate arthrodesis with excision of the scaphoid with or without the triquetrum as an alternative to 4-corner fusion for SLAC wrists. Long-term outcomes of these 2 surgical options are similar, according to 1 recent series.[114]

Wrist arthroplasty is a motion-preserving option that is generally reserved for lower-demand patients with advanced disease. Patients with diffuse degenerative changes with higher activity demands and poor bone stock are not good candidates for total wrist arthroplasty, at least with the current designs, because of high rates of distal component loosening.[115] In those patients, complete wrist arthrodesis provides predictable pain relief as well as functional impairment resulting from motion loss. Wrist hemiarthroplasty is a newer motion-sparing technique that may be an option for younger, more active patients, but there are limited available data at this time (Fig. 16).[116]

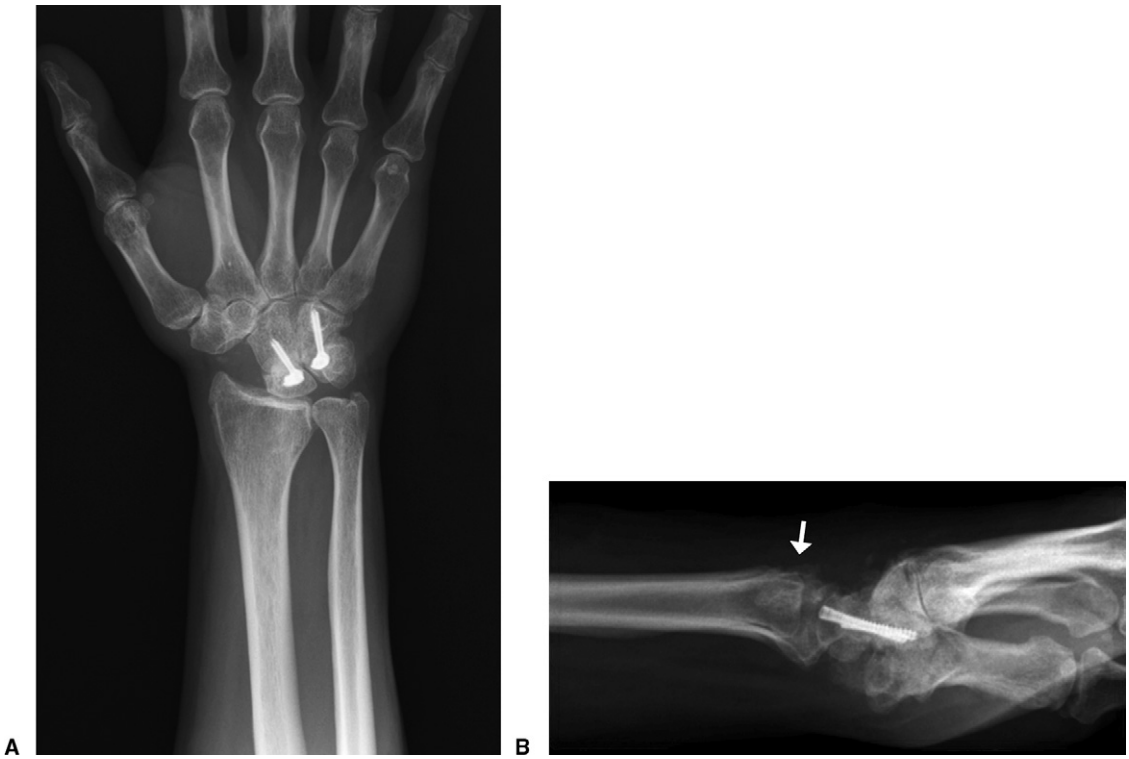

FIGURE 15: A Four-corner arthrodesis is designed to restore stability while maintaining motion of the radiocarpal joint. **B** The dorsal lip of the distal radius (arrow) can be excised if impingement is noted after fixation.

FIGURE 16: A AP and **B** lateral wrist radiographs demonstrating a wrist hemiarthroplasty. Wrist hemiarthroplasty is an option for advanced-stage disease, but there are limited available data at this time. (Reprinted with permission from Boyer JS, Adams B. Distal radius hemiarthroplasty combined with proximal row carpectomy: case report. Iowa Orthop J 2010;30:168–173.)

Stage IV: outcomes

DiDonna and colleagues[109] reported relatively good long-term outcomes after PRC for SLAC disease. In their series of 22 wrists, they reported an average flexion-extension arc of 72° and average grip strength of 91% of the contralateral side after a minimum follow-up period of 10 years. Outcomes were associated with patient age at the time of the surgical procedure; patients older than 35 years had superior outcomes. They had 4 failures requiring complete wrist arthrodesis at a mean of 7 years after PRC, and all 4 failures occurred in patients who were 35 years of age or younger at the time of the PRC.

Proximal row carpectomy compares favorably with 4-corner fusion in several studies in terms of range of motion and grip strength.[71,117–121] A recent systematic review of 52 articles on outcomes for SLAC and scaphoid nonunion advanced collapse patients undergoing PRC or 4-corner fusion confirmed that both procedures lead to similar postoperative improvements in pain, subjective outcome measures, and grip strength.[122] Proximal row carpectomy may result in better range of movement and fewer complications specific to 4-corner fusion, such as nonunion, impingement, and hardware failure.[122] However, PRC is associated with a higher risk of subsequent osteoarthritis, because the articulating surfaces are not congruent, generating abnormal sheer forces during wrist motion.[123] Because neither procedure is without the potential for complication, patients should be advised that these procedures are collectively referred to as "salvage" procedures for a wrist that otherwise is a candidate for complete wrist arthrodesis. Lunocapitate fusions also have long-term results to similar 4-corner arthrodesis.[114] Ferreres and colleagues[114] reported that a series of 17 patients treated with lunocapitate fusions for SLAC and scaphoid nonunion advanced collapse wrists had similar 8- to 12-year follow-up results compared with 4-corner arthrodeses.

Current designs for total wrist arthroplasty are associated with high failure rates, most often resulting from distal component loosening.[115] Ward and colleagues[115] reported a 50% revision rate in a series of 20 rheumatoid patients treated with the Universal wrist prosthesis after a mean follow-up period of 7.3 years. There are limited data concerning the long-term use of total wrist arthroplasty in nonrheumatoid patients with advanced SLAC disease, but concerns persist over component loosing with the current, available designs.

We reserve the PRC for older, lower-demand patients with stage I to II SLAC disease and intact volar extrinsic ligaments. Scaphoid excision and 4-corner arthrodesis or lunocapitate arthrodesis with excision of both the scaphoid and triquetrum may be promising choices for younger, higher-demand patients.[124,125] Wrist hemiarthroplasty[116] may be a future option for young or active patients, but there are no supporting data available to date. Newer designs of total wrist arthroplasty and pyrocarbon implants may also have a role in the future, but lack sufficient follow-up data to advocate their use at present.

In summary, the SLIL is the critical stabilizer of a delicately balanced system of joints. Carpal alignment may be maintained acutely after isolated disruption of this ligament because of a complex array of secondary stabilizers. Disruption of this important ligament is generally the first stage of a slow and steady progression toward wrist dysfunction and degenerative disease. It is therefore important to appreciate SL instability as a spectrum of injury. Our classification scheme divides this disorder into 5 stages based on an appreciation of the key concepts: static versus dynamic instability, repairable versus irreparable ligament, reducible versus irreducible deformity, and combined coronal and sagittal plane pathology. Treatment is then tailored to the stage of injury and is individualized to address the degree of anatomic and kinematic alteration.

REFERENCES

1. Wolfe SW, Neu C, Crisco JJ. In vivo scaphoid, lunate, and capitate kinematics in flexion and in extension. J Hand Surg 2000;25A:860–869.
2. Landsmeer J. Studies in the anatomy of articulation. 1. The equilibrium of the "intercalated" bone. Acta Morphol Neerl Scand 1961;3:287–303.
3. Linscheid RL, Dobyns JH, Beabout JW, Bryan RS. Traumatic instability of the wrist. Diagnosis, classification, and pathomechanics. J Bone Joint Surg 1972;54A:1612–1632.
4. Berger RA. The gross and histologic anatomy of the scapholunate interosseous ligament. J Hand Surg 1996;21A:170–178.
5. Berger RA, Imeada T, Berglund L, An KN. Constraint and material properties of the subregions of the scapholunate interosseous ligament. J Hand Surg 1999;24A:953–962.
6. Drewniany JJ, Palmer AK, Flatt AE. The scaphotrapezial ligament complex: an anatomic and biomechanical study. J Hand Surg 1985;10A:492–498.
7. Garcia-Elias M, Lluch AL, Stanley JK. Three-ligament tenodesis for the treatment of scapholunate dissociation: indications and surgical technique. J Hand Surg 2006;31A:125–134.
8. Short WH, Werner FW, Green JK, Masaoka S. Biomechanical evaluation of the ligamentous stabilizers of the scaphoid and lunate: Part II. J Hand Surg 2005;30A:24–34.
9. Short WH, Werner FW, Green JK, Sutton LG, Brutus JP. Biomechanical evaluation of the ligamentous stabilizers of the scaphoid and lunate: part III. J Hand Surg 2007;32A:297–309.
10. Weber ER. Concepts governing the rotational shift of the intercalated segment of the carpus. Orthop Clin North Am 1984;15A:193–207.
11. Macconaill MA. The mechanical anatomy of the carpus and its bearings on some surgical problems. J Anat 1941;75:166–175.
12. Craigen MA, Stanley JK. Wrist kinematics. Row, column or both? J Hand Surg 1995;20B:165–170.

13. Garcia-Elias M, Pitagoras T, Gilabert-Senar A. Relationship between joint laxity and radio-ulno-carpal joint morphology. J Hand Surg 2003;28B:158–162.
14. Moojen TM, Snel JG, Ritt MJ, Venema HW, Kauer JM, Bos KE. In vivo analysis of carpal kinematics and comparative review of the literature. J Hand Surg 2003;28A:81–87.
15. Crisco JJ, Coburn JC, Moore DC, Akelman E, Weiss AP, Wolfe SW. In vivo radiocarpal kinematics and the dart thrower's motion. J Bone Joint Surg 2005;87A:2729–2740.
16. Ishikawa J, Cooney WP III, Niebur G, An KN, Minami A, Kaneda K. The effects of wrist distraction on carpal kinematics. J Hand Surg 1999;24A:113–120.
17. Moritomo H, Apergis EP, Herzberg G, Werner FW, Wolfe SW, Garcia-Elias M. 2007 IFSSH committee report of wrist biomechanics committee: biomechanics of the so-called dart-throwing motion of the wrist. J Hand Surg 2007;32A:1447–1453.
18. Werner FW, Green JK, Short WH, Masaoka S. Scaphoid and lunate motion during a wrist dart throw motion. J Hand Surg 2004;29A:418–422.
19. Wolfe SW, Crisco JJ, Orr CM, Marzke MW. The dart-throwing motion of the wrist: is it unique to humans? J Hand Surg 2006;31A:1429–1437.
20. Palmer AK, Werner FW, Murphy D, Glisson R. Functional wrist motion: a biomechanical study. J Hand Surg 1985;10A:39–46.
21. Blevens AD, Light TR, Jablonsky WS, Smith DG, Patwardhan AG, Guay ME, et al. Radiocarpal articular contact characteristics with scaphoid instability. J Hand Surg 1989;14A:781–790.
22. Meade TD, Schneider LH, Cherry K. Radiographic analysis of selective ligament sectioning at the carpal scaphoid: a cadaver study. J Hand Surg 1990;15A:855–862.
23. Linscheid RL, Dobyns JH. Treatment of scapholunate dissociation. Rotatory subluxation of the scaphoid. Hand Clin 1992;8:645–652.
24. Wolfe SW, Katz LD, Crisco JJ. Radiographic progression to dorsal intercalated segment instability. Orthopedics 1996;19:691–695.
25. Werner FW, Short WH, Green JK, Evans PJ, Walker JA. Severity of scapholunate instability is related to joint anatomy and congruency. J Hand Surg 2007;32A:55–60.
26. Rhee PC, Moran SL, Shin AY. Association between lunate morphology and carpal collapse in cases of scapholunate dissociation. J Hand Surg 2009;34A:1633–1639.
27. Berdia S, Wolfe S. Anatomy, biomechanics, and natural history of scapholunate interosseous ligament injuries. Atl Hand Clin 2003;8:191–199.
28. Watson H, Ottoni L, Pitts EC, Handal AG. Rotary subluxation of the scaphoid: a spectrum of instability. J Hand Surg 1993;18B:62–64.
29. Nathan R, Blatt G. Rotatory subluxation of the scaphoid revisited. Hand Clin 2000;16:417–431.
30. Definition of carpal instability. The Anatomy and Biomechanics Committee of the International Federation of Societies for Surgery of the Hand. J Hand Surg 1999;24A:866–867.
31. Manuel J, Moran SL. The diagnosis and treatment of scapholunate instability. Hand Clin 2010;26:129–144.
32. Watson HK, Ashmead D IV, Makhlouf MV. Examination of the scaphoid. J Hand Surg 1988;13A:657–660.
33. Weiss AP, Akelman E, Lambiase R. Comparison of the findings of triple-injection cinearthrography of the wrist with those of arthroscopy. J Bone Joint Surg 1996;78A:348–356.
34. Wolfe SW, Gupta A, Crisco JJ III. Kinematics of the scaphoid shift test. J Hand Surg 1997;22A:801–806.
35. Yang Z, Mann FA, Gilula LA, Haerr C, Larsen CF. Scaphopisocapitate alignment: criterion to establish a neutral lateral view of the wrist. Radiology 1997;205:865–869.
36. Larsen CF, Stigsby B, Lindequist S, Bellstrom T, Mathiesen FK, Ipsen T. Observer variability in measurements of carpal bone angles on lateral wrist radiographs. J Hand Surg 1991;16A:893–898.
37. Schimmerl-Metz SM, Metz VM, Totterman SM, Mann FA, Gilula LA. Radiologic measurement of the scapholunate joint: implications of biologic variation in scapholunate joint morphology. J Hand Surg 1999;24A:1237–1244.
38. Cautilli GP, Wehbe MA. Scapho-lunate distance and cortical ring sign. J Hand Surg 1991;16A:501–503.
39. Lee SK, Desai H, Silver B, Dhaliwal G, Paksima N. Comparison of radiographic stress views for scapholunate dynamic instability in a cadaver model. J Hand Surg 2011;36A:1149–1157.
40. Yamaguchi S, Beppu M, Matsushita K, Takahashi K. The carpal stretch test at the scapholunate joint. J Hand Surg 1998;23A:617–625.
41. Chung KC, Zimmerman NB, Travis MT. Wrist arthrography versus arthroscopy: a comparative study of 150 cases. J Hand Surg 1996;21A:591–594.
42. Cantor RM, Stern PJ, Wyrick JD, Michaels SE. The relevance of ligament tears or perforations in the diagnosis of wrist pain: an arthrographic study. J Hand Surg 1994;19A:945–953.
43. Herbert TJ, Faithfull RG, McCann DJ, Ireland J. Bilateral arthrography of the wrist. J Hand Surg 1990;15B:233–235.
44. Bille B, Harley B, Cohen H. A comparison of CT arthrography of the wrist to findings during wrist arthroscopy. J Hand Surg 2007;32A:834–841.
45. Scheck RJ, Kubitzek C, Hierner R, Szeimies U, Pfluger T, Wilhelm K, et al. The scapholunate interosseous ligament in MR arthrography of the wrist: correlation with non-enhanced MRI and wrist arthroscopy. Skeletal Radiol 1997;26:263–271.
46. Smith DK. Volar carpal ligaments of the wrist: normal appearance on multiplanar reconstructions of three-dimensional Fourier transform MR imaging. AJR Am J Roentgenol 1993;161:353–357.
47. Berger RA, Linscheid RL, Berquist TH. Magnetic resonance imaging of the anterior radiocarpal ligaments. J Hand Surg 1994;19A:295–303.
48. Zanetti M, Saupe N, Nagy L. Role of MR imaging in chronic wrist pain. Eur Radiol 2007;17:927–938.
49. Schadel-Hopfner M, Iwinska-Zelder J, Braus T, Bohringer G, Klose KJ, Gotzen L. MRI versus arthroscopy in the diagnosis of scapholunate ligament injury. J Hand Surg 2001;26B:17–21.
50. Haims AH, Schweitzer ME, Morrison WB, Deely D, Lange RC, Osterman AL, et al. Internal derangement of the wrist: indirect MR arthrography versus unenhanced MR imaging. Radiology 2003;227:701–707.
51. Manton GL, Schweitzer ME, Weishaupt D, Morrison WB, Osterman AL, Culp RW, et al. Partial interosseous ligament tears of the wrist: difficulty in utilizing either primary or secondary MRI signs. J Comput Assist Tomogr 2001;25:671–676.
52. Magee T. Comparison of 3-T MRI and arthroscopy of intrinsic wrist ligament and TFCC tears. AJR Am J Roentgenol 2009;192:80–85.
53. Rotman MB, Manske PR, Pruitt DL, Szerzinski J. Scaphocapitolunate arthrodesis. J Hand Surg 1993;18A:26–33.
54. Ruch DS, Bowling J. Arthroscopic assessment of carpal instability. Arthroscopy 1998;14:675–681.
55. Geissler WB, Freeland AE, Savoie FH, McIntyre LW, Whipple TL. Intracarpal soft-tissue lesions associated with an intra-articular fracture of the distal end of the radius. J Bone Joint Surg 1996;78A:357–365.
56. Kuo CE, Wolfe SW. Scapholunate instability: current concepts in diagnosis and management. J Hand Surg 2008;33A:998–1013.
57. Mayfield JK, Johnson RP, Kilcoyne RK. Carpal dislocations: pathomechanics and progressive perilunar instability. J Hand Surg 1980;5:226–241.
58. Watson HK, Ballet FL. The SLAC wrist: scapholunate advanced collapse pattern of degenerative arthritis. J Hand Surg 1984;9A:358–365.
59. Weiss KE, Rodner CM. Osteoarthritis of the wrist. J Hand Surg 2007;32A:725–746.
60. Kang L, Wolfe SW. Scapholunate instability: diagnosis and man-

agement. ASSH Master Skills in Wrist and Elbow Athroscopy and Reconstruction. Chicago: ASSH, 2007.
61. Moran SL, Cooney WP, Berger RA, Strickland J. Capsulodesis for the treatment of chronic scapholunate instability. J Hand Surg 2005;30A:16–23.
62. Danoff JR, Karl JW, Birman MV, Rosenwasser MP. The use of thermal shrinkage for scapholunate instability. Hand Clin 2011;27: 309–317.
63. Weiss AP, Sachar K, Glowacki KA. Arthroscopic debridement alone for intercarpal ligament tears. J Hand Surg 1997;22A:344–349.
64. Ruch DS, Poehling GG. Arthroscopic management of partial scapholunate and lunotriquetral injuries of the wrist. J Hand Surg 1996;21A:412–417.
65. Darlis NA, Weiser RW, Sotereanos DG. Partial scapholunate ligament injuries treated with arthroscopic debridement and thermal shrinkage. J Hand Surg 2005;30A:908–914.
66. Blatt G. Capsulodesis in reconstructive hand surgery. Dorsal capsulodesis for the unstable scaphoid and volar capsulodesis following excision of the distal ulna. Hand Clin 1987;3:81–102.
67. Slater RR Jr, Szabo RM, Bay BK, Laubach J. Dorsal intercarpal ligament capsulodesis for scapholunate dissociation: biomechanical analysis in a cadaver model. J Hand Surg 1999;24A:232–239.
68. Lavernia CJ, Cohen MS, Taleisnik J. Treatment of scapholunate dissociation by ligamentous repair and capsulodesis. J Hand Surg 1992;17A:354–359.
69. Wolfe SW. "Scapholunate ligament repair" [video podcast]. New York: Hospital for Special Surgery. Available: http://www.hss.edu/podcasts.asp. Accessed: March, 2012.
70. Tomaino MM, Delsignore J, Burton RI. Long-term results following proximal row carpectomy. J Hand Surg 1994;19A:694–703.
71. Uhl RL, Williamson SC, Bowman MW, Sotereanos DG, Osterman AL. Dorsal capsulodesis using suture anchors. Am J Orthop (Belle Mead NJ) 1997;26:547–548.
72. Gajendran VK, Peterson B, Slater RR Jr, Szabo RM. Long-term outcomes of dorsal intercarpal ligament capsulodesis for chronic scapholunate dissociation. J Hand Surg 2007;32A:1323–1333.
73. Wintman BI, Gelberman RH, Katz JN. Dynamic scapholunate instability: results of operative treatment with dorsal capsulodesis. J Hand Surg 1995;20A:971–979.
74. Bickert B, Sauerbier M, Germann G. Scapholunate ligament repair using the Mitek bone anchor. J Hand Surg 2000;25B:188–192.
75. Rosati M, Parchi P, Cacianti M, Poggetti A, Lisanti M. Treatment of acute scapholunate ligament injuries with bone anchor. Musculoskelet Surg 2010;94:25–32.
76. Pomerance J. Outcome after repair of the scapholunate interosseous ligament and dorsal capsulodesis for dynamic scapholunate instability due to trauma. J Hand Surg 2006;31A:1380–1386.
77. Herbert TJ. Acute rotary dislocation of the scaphoid: a new technique of repair using Herbert screw fixation across the scapholunate joint. World J Surg 1991;15:463–469.
78. Brunelli GA, Brunelli GR. A new technique to correct carpal instability with scaphoid rotary subluxation: a preliminary report. J Hand Surg 1995;20A:S82–S85.
79. Talwalkar SC, Edwards AT, Hayton MJ, Stilwell JH, Trail IA, Stanley JK. Results of tri-ligament tenodesis: a modified Brunelli procedure in the management of scapholunate instability. J Hand Surg 2006;31B:110–117.
80. Van Den Abbeele KL, Loh YC, Stanley JK, Trail IA. Early results of a modified Brunelli procedure for scapholunate instability. J Hand Surg 1998;23B:258–261.
81. De Smet L, Van Hoonacker P. Treatment of chronic static scapholunate dissociation with the modified Brunelli technique: preliminary results. Acta Orthop Belg 2007;73:188–191.
82. Salva-Coll G, Garcia-Elias M, Llusa-Perez M, Rodriguez-Baeza A. The role of the flexor carpi radialis muscle in scapholunate instability. J Hand Surg 2011;36A:31–36.
83. Peterson SL, Freeland AE. Scapholunate stabilization with dynamic extensor carpi radialis longus tendon transfer. J Hand Surg 2010;35A:2093–2100.
84. Bleuler P, Shafighi M, Donati OF, Gurunluoglu R, Constantinescu MA. Dynamic repair of scapholunate dissociation with dorsal extensor carpi radialis longus tenodesis. J Hand Surg 2008;33A:281–284.
85. Weiss AP. Scapholunate ligament reconstruction using a bone-retinaculum-bone autograft. J Hand Surg 1998;23A:205–215.
86. Svoboda SJ, Eglseder WA Jr, Belkoff SM. Autografts from the foot for reconstruction of the scapholunate interosseous ligament. J Hand Surg 1995;20A:980–985.
87. Hofstede DJ, Ritt MJ, Bos KE. Tarsal autografts for reconstruction of the scapholunate interosseous ligament: a biomechanical study. J Hand Surg 1999;24A:968–976.
88. Harvey EJ, Berger RA, Osterman AL, Fernandez DL, Weiss AP. Bone-tissue-bone repairs for scapholunate dissociation. J Hand Surg 2007;32A:256–264.
89. Rosenwasser MP, Miyasajsa KC, Strauch RJ. The RASL procedure: reduction and association of the scaphoid and lunate using the Herbert screw. Tech Hand Up Extrem Surg 1997;1:263–272.
90. Hom S, Ruby LK. Attempted scapholunate arthrodesis for chronic scapholunate dissociation. J Hand Surg 1991;16A:334–339.
91. Harvey EJ, Hanel D, Knight JB, Tencer AF. Autograft replacements for the scapholunate ligament: a biomechanical comparison of hand-based autografts. J Hand Surg 1999;24A:963–967.
92. Caloia M, Caloia H, Pereira E. Arthroscopic scapholunate joint reduction. Is an effective treatment for irreparable scapholunate ligament tears? Clin Orthop Relat Res 2012;470:972–978.
93. Peterson HA, Lipscomb PR. Intercarpal arthrodesis. Arch Surg 1967;95:127–134.
94. Watson HK, Belniak R, Garcia-Elias M. Treatment of scapholunate dissociation: preferred treatment—STT fusion vs other methods. Orthopedics 1991;14:365–368, discussion 368–370.
95. Viegas SF, Patterson RM, Peterson PD, Pogue DJ, Jenkins DK, Sweo TD, et al. Evaluation of the biomechanical efficacy of limited intercarpal fusions for the treatment of scapho-lunate dissociation. J Hand Surg 1990;15A:120–128.
96. Kleinman WB, Carroll C IV. Scapho-trapezio-trapezoid arthrodesis for treatment of chronic static and dynamic scapho-lunate instability: a 10-year perspective on pitfalls and complications. J Hand Surg 1990;15A:408–414.
97. Watson HK, Ryu J, Akelman E. Limited triscaphoid intercarpal arthrodesis for rotatory subluxation of the scaphoid. J Bone Joint Surg 1986;68A:345–349.
98. Pisano SM, Peimer CA, Wheeler DR, Sherwin F. Scaphocapitate intercarpal arthrodesis. J Hand Surg 1991;16A:328–333.
99. Hofmeister EP, Moran SL, Shin AY. Anterior and posterior interosseous neurectomy for the treatment of chronic dynamic instability of the wrist. Hand (N Y) 2006;1:63–70.
100. Nakamura T, Cooney WP III, Lui WH, Haugstvedt JR, Zhao KD, Berglund L, et al. Radial styloidectomy: a biomechanical study on stability of the wrist joint. J Hand Surg 2001;26A:85–93.
101. Strauch RJ. Scapholunate advanced collapse and scaphoid nonunion advanced collapse arthritis—update on evaluation and treatment. J Hand Surg 2011;36A:729–735.
102. Crisco JJ, Heard WM, Rich RR, Paller DJ, Wolfe SW. The mechanical axes of the wrist are oriented obliquely to the anatomical axes. J Bone Joint Surg 2011;93A:169–177.
103. Leventhal EL, Moore DC, Akelman E, Wolfe SW, Crisco JJ. Carpal and forearm kinematics during a simulated hammering task. J Hand Surg 2010;35A:1097–1104.
104. Calfee RP, Leventhal EL, Wilkerson J, Moore DC, Akelman E, Crisco JJ. Simulated radioscapholunate fusion alters carpal kinematics while preserving dart-thrower's motion. J Hand Surg 2008; 33A:503–510.
105. Murray PM. Radioscapholunate arthrodesis. Hand Clin 2005;21: 561–566.

106. Garcia-Elias M, Goubier JN. Radio-scapho-lunate arthrodesis with distal scaphoid excision. Chir Main 2008;27:227–231.
107. McCombe D, Ireland DC, McNab I. Distal scaphoid excision after radioscaphoid arthrodesis. J Hand Surg 2001;26A:877–882.
108. Pervaiz K, Bowers WH, Isaacs JE, Owen JR, Wayne JS. Range of motion effects of distal pole scaphoid excision and triquetral excision after radioscapholunate fusion: a cadaver study. J Hand Surg 2009;34A:832–837.
109. DiDonna ML, Kiefhaber TR, Stern PJ. Proximal row carpectomy: study with a minimum of ten years of follow-up. J Bone Joint Surg 2004;86A:2359–2365.
110. Stern PJ, Agabegi SS, Kiefhaber TR, Didonna ML. Proximal row carpectomy. J Bone Joint Surg 2005;87A(Suppl 1):166–174.
111. Shindle MK, Burton KJ, Weiland AJ, Domb BG, Wolfe SW. Complications of circular plate fixation for four-corner arthrodesis. J Hand Surg 2007;32B:50–53.
112. Vance MC, Hernandez JD, Didonna ML, Stern PJ. Complications and outcome of four-corner arthrodesis: circular plate fixation versus traditional techniques. J Hand Surg 2005;30A:1122–1127.
113. Collins ED, Nolla J. Spider plate fixation: no significant improvement in limited wrist arthrodesis. Tech Hand Up Extrem Surg 2008;12:94–99.
114. Ferreres A, Garcia-Elias M, Plaza R. Long-term results of lunocapitate arthrodesis with scaphoid excision for SLAC and SNAC wrists. J Hand Surg 2009;34E:603–608.
115. Ward CM, Kuhl T, Adams BD. Five to ten-year outcomes of the Universal total wrist arthroplasty in patients with rheumatoid arthritis. J Bone Joint Surg 2011;93A:914–919.
116. Boyer JS, Adams B. Distal radius hemiarthroplasty combined with proximal row carpectomy: case report. Iowa Orthop J 2010;30:168–173.
117. Ashmead D IV, Watson HK, Damon C, Herber S, Paly W. Scapholunate advanced collapse wrist salvage. J Hand Surg 1994;19A:741–750.
118. Wyrick JD, Stern PJ, Kiefhaber TR. Motion-preserving procedures in the treatment of scapholunate advanced collapse wrist: proximal row carpectomy versus four-corner arthrodesis. J Hand Surg 1995;20A:965–970.
119. Krakauer JD, Bishop AT, Cooney WP. Surgical treatment of scapholunate advanced collapse. J Hand Surg 1994;19A:751–759.
120. Cohen MS, Kozin SH. Degenerative arthritis of the wrist: proximal row carpectomy versus scaphoid excision and four-corner arthrodesis. J Hand Surg 2001;26A:94–104.
121. Dacho AK, Baumeister S, Germann G, Sauerbier M. Comparison of proximal row carpectomy and midcarpal arthrodesis for the treatment of scaphoid nonunion advanced collapse (SNAC-wrist) and scapholunate advanced collapse (SLAC-wrist) in stage II. J Plast Reconstr Aesthet Surg 2008;61:1210–1218.
122. Mulford JS, Ceulemans LJ, Nam D, Axelrod TS. Proximal row carpectomy vs four corner fusion for scapholunate (Slac) or scaphoid nonunion advanced collapse (Snac) wrists: a systematic review of outcomes. J Hand Surg 2009;34E:256–263.
123. Blankenhorn BD, Pfaeffle HJ, Tang P, Robertson D, Imbriglia J, Goitz RJ. Carpal kinematics after proximal row carpectomy. J Hand Surg 2007;32A:37–46.
124. Calandruccio JH, Gelberman RH, Duncan SF, Goldfarb CA, Pae R, Gramig W. Capitolunate arthrodesis with scaphoid and triquetrum excision. J Hand Surg 2000;25A:824–832.
125. Goubier JN, Teboul F. Capitolunate arthrodesis with compression screws. Tech Hand Up Extrem Surg 2007;11:24–28.